

Supplementary Appendix

This appendix has been provided by the authors to give readers additional information about their work.

Supplement to: Bangalore S, Sharma A, Slotwiner A, et al. ST-segment elevation in patients with Covid-19 — a case series. *N Engl J Med* 2020;382:2478-80. DOI: 10.1056/NEJMc2009020

Supplementary Appendix

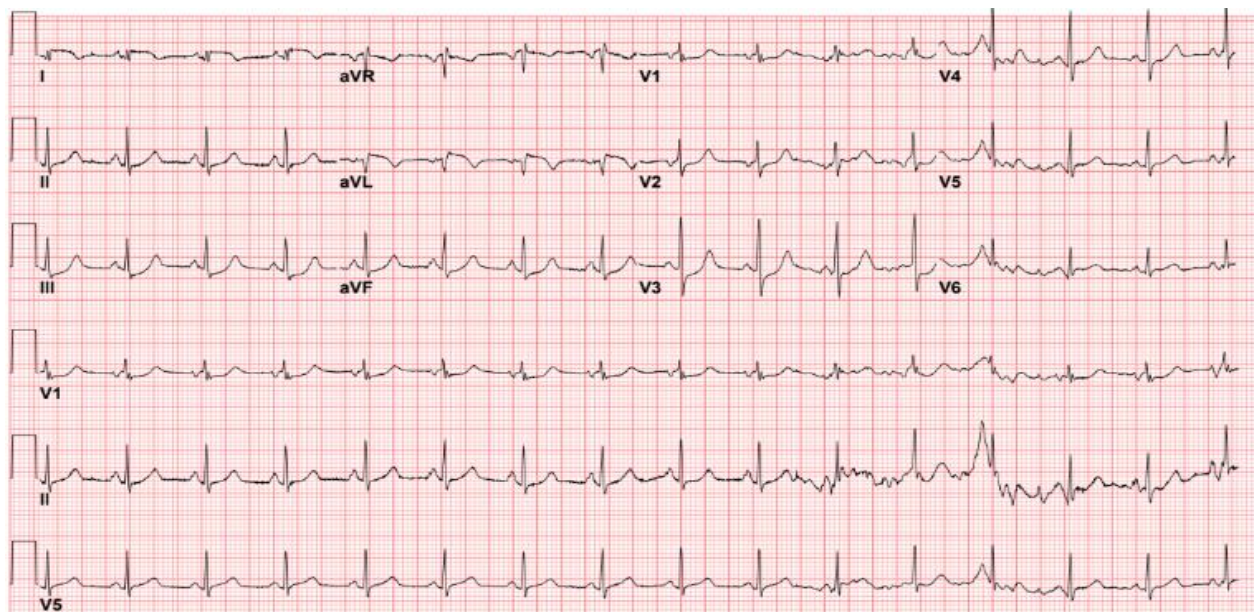
This appendix has been provided by the authors to give readers additional information about their work.

Contents

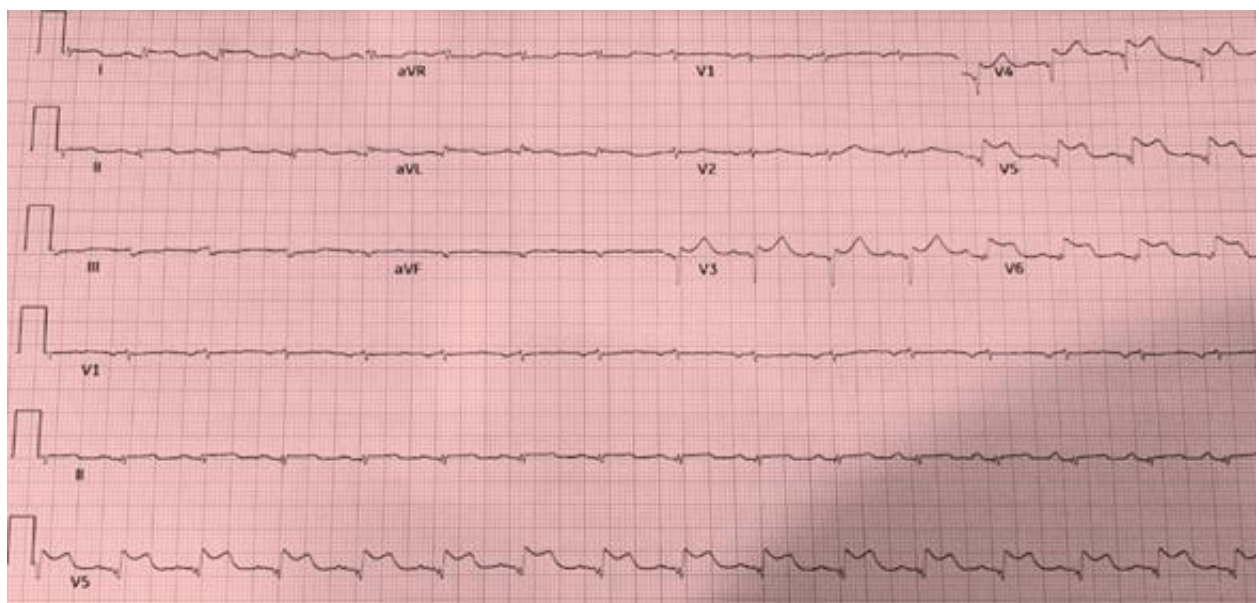
Figure S1. Electrocardiogram.....	2
Figure S2A. Timing of ST-segment elevation, length of stay and outcome.....	11
Figure S2B. Peak troponin levels.....	12
Figure S2C. D-dimer levels	13
Figure S3. Coronary angiography.....	14
Figure S4. Electrocardiogram, echocardiogram and coronary angiography	19

Figure S1. Electrocardiogram

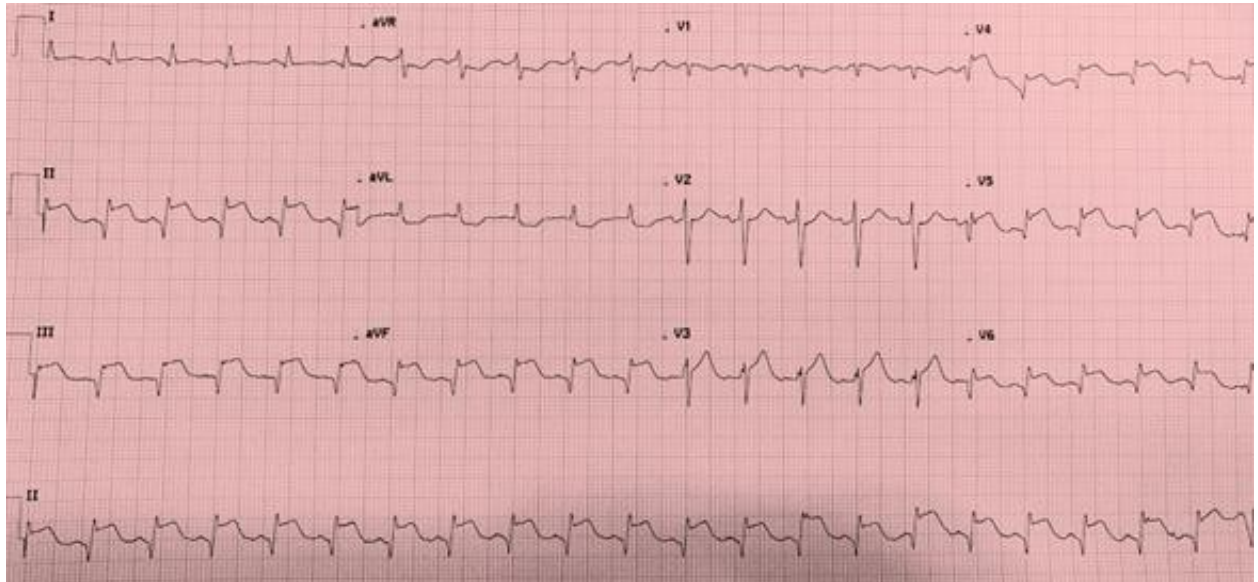
Patient #1



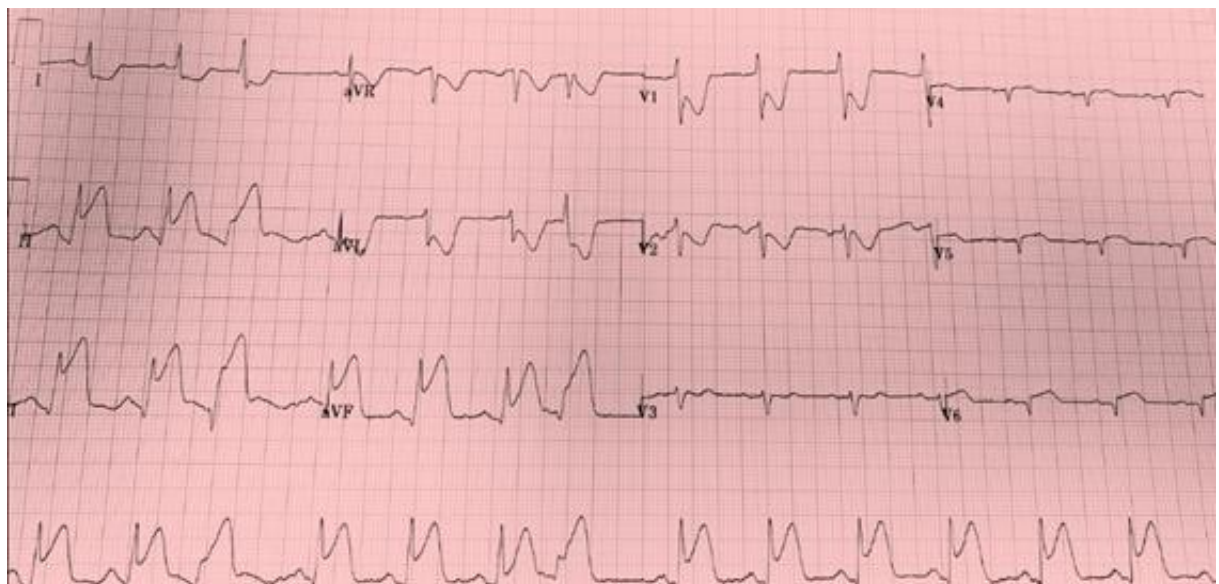
Patient #2



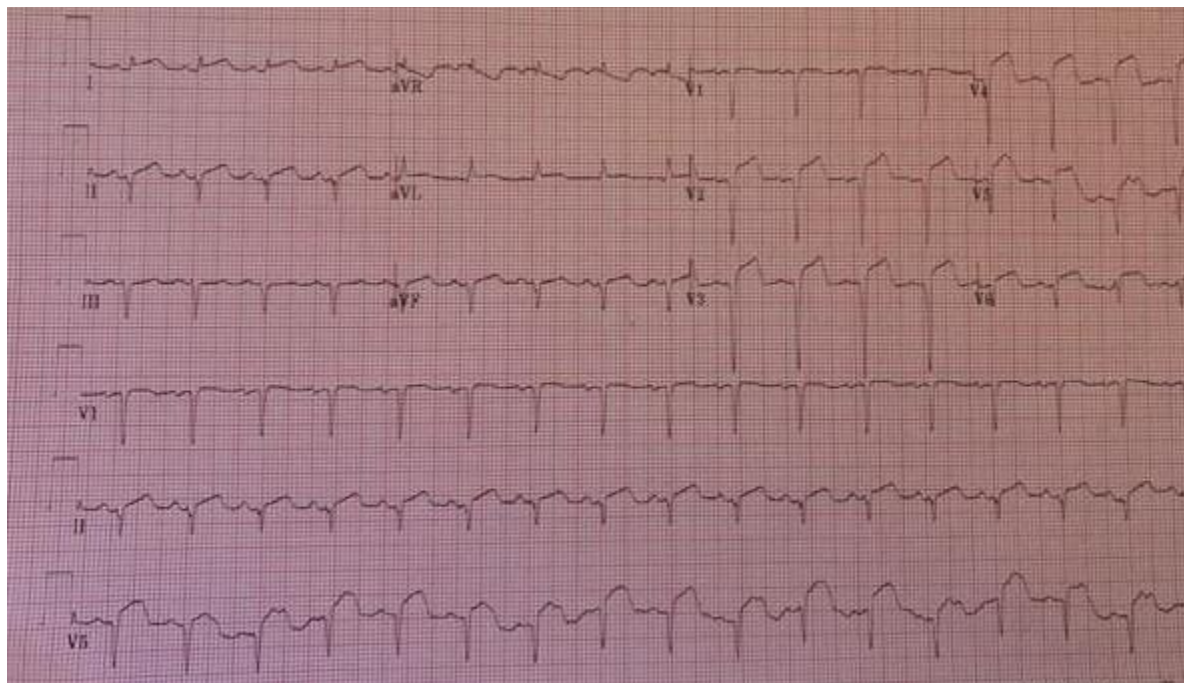
Patient #3



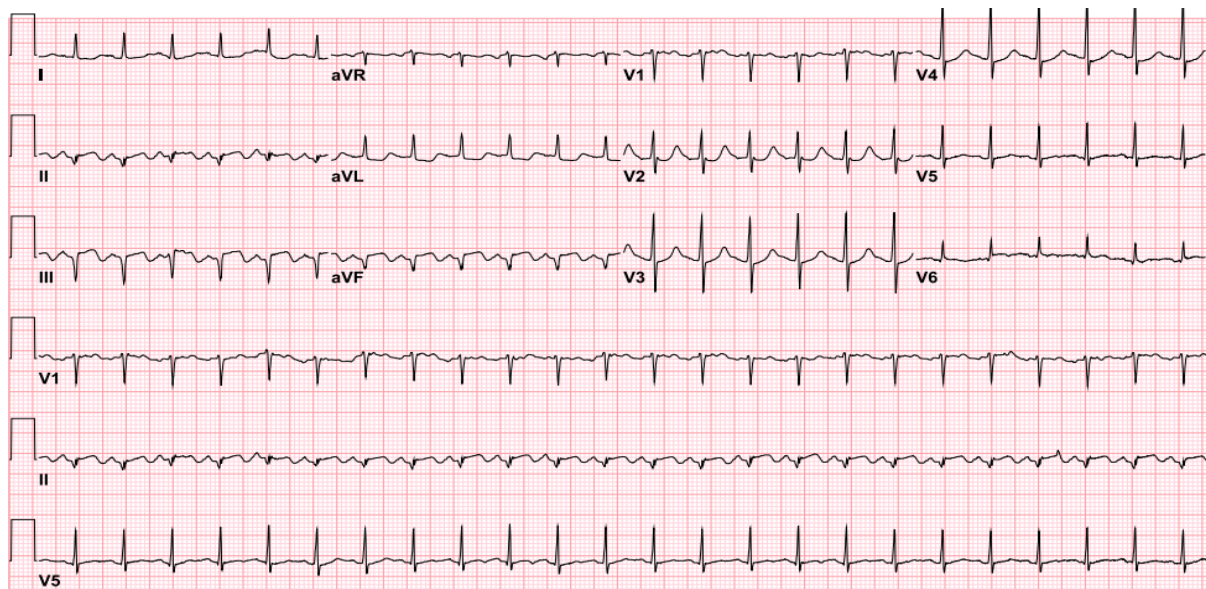
Patient #4



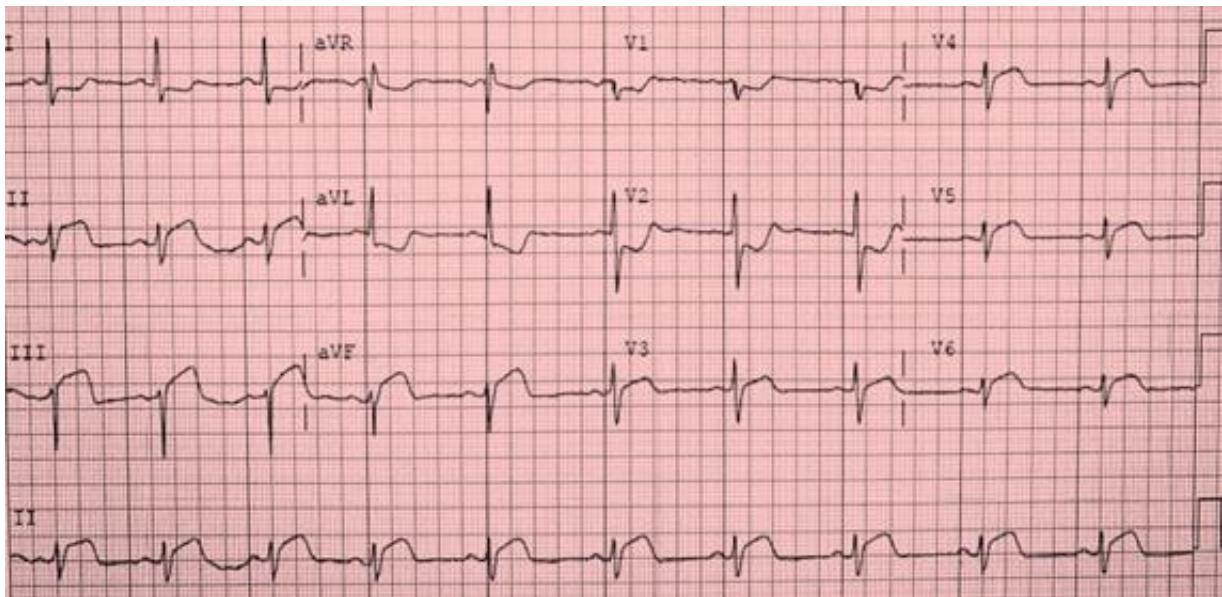
Patient #5



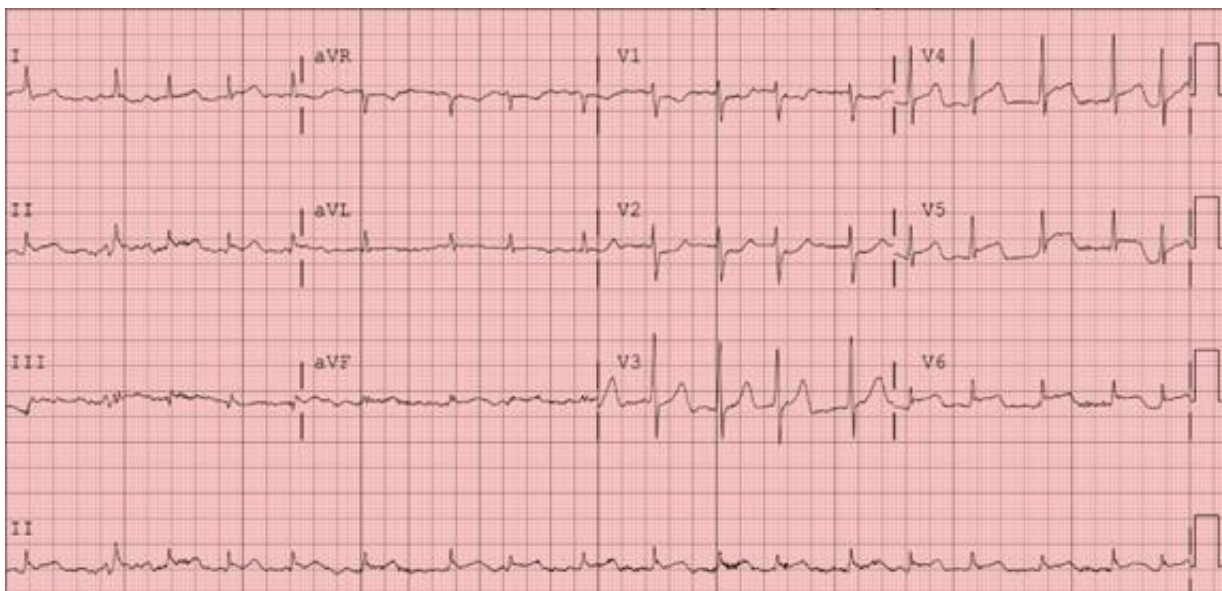
Patient #6



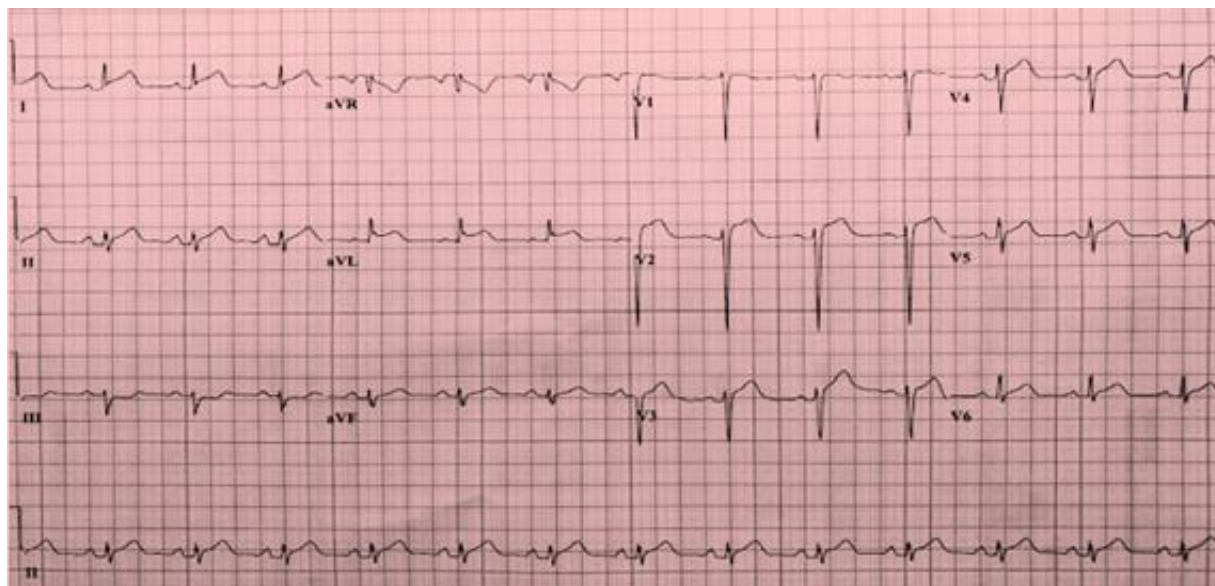
Patient #7



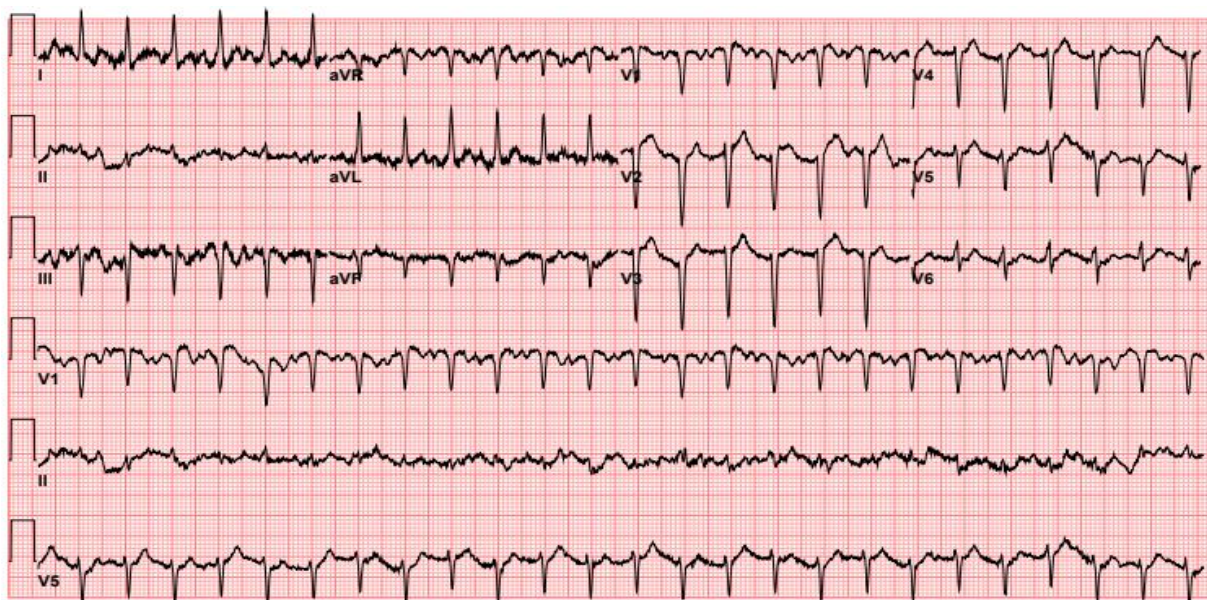
Patient #8



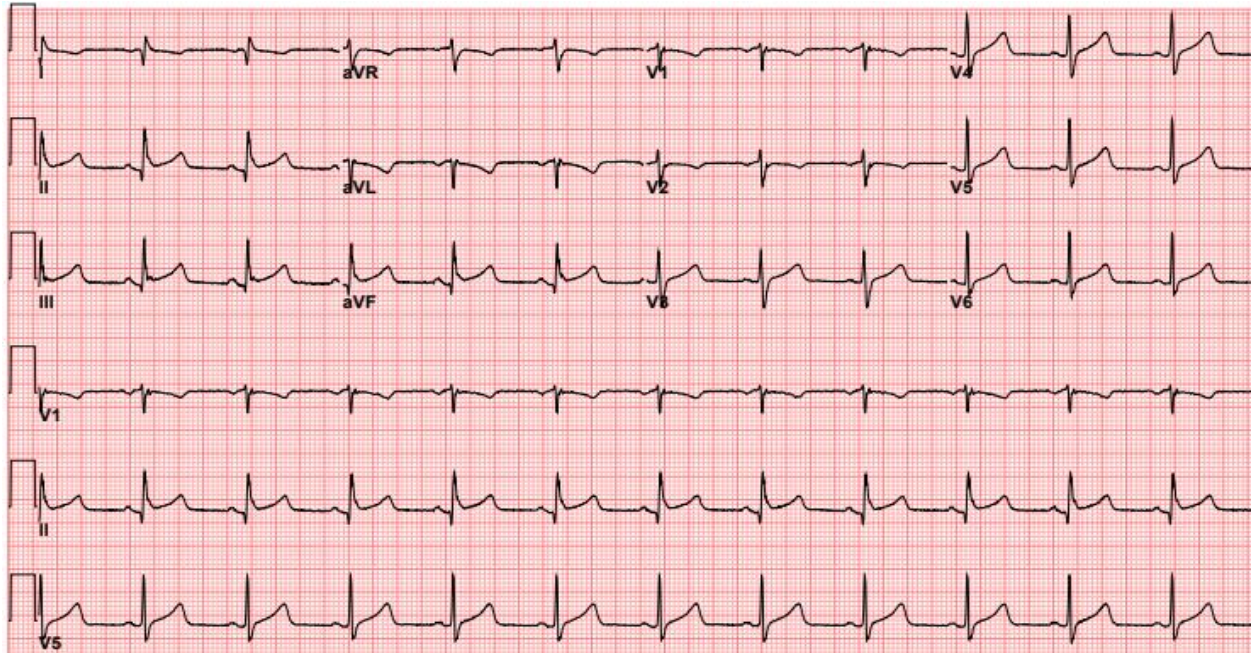
Patient #9



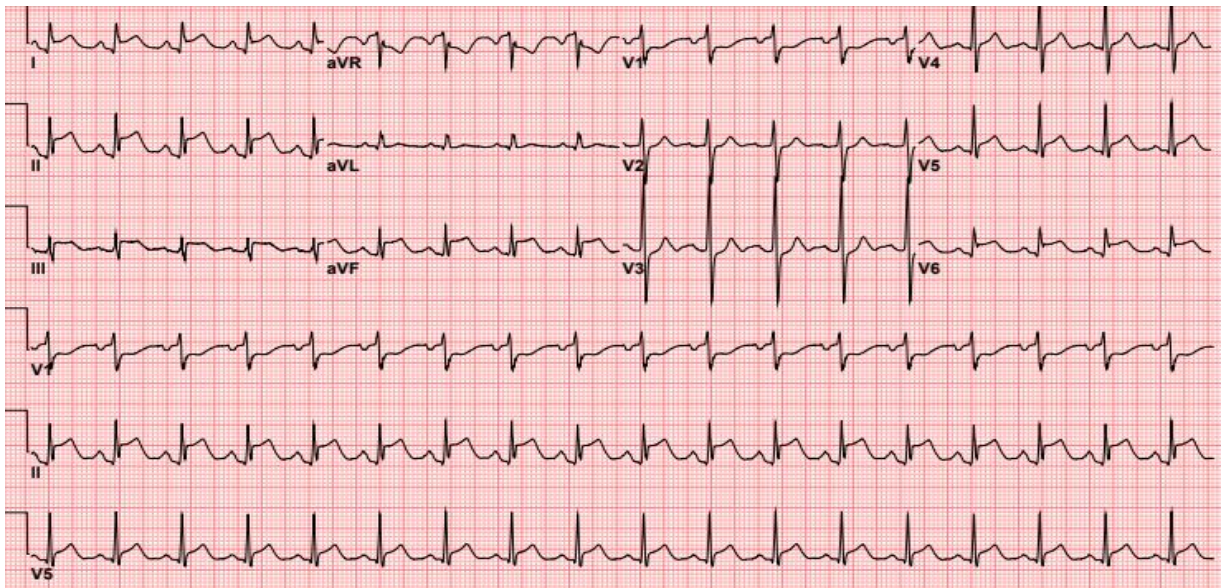
Patient #10



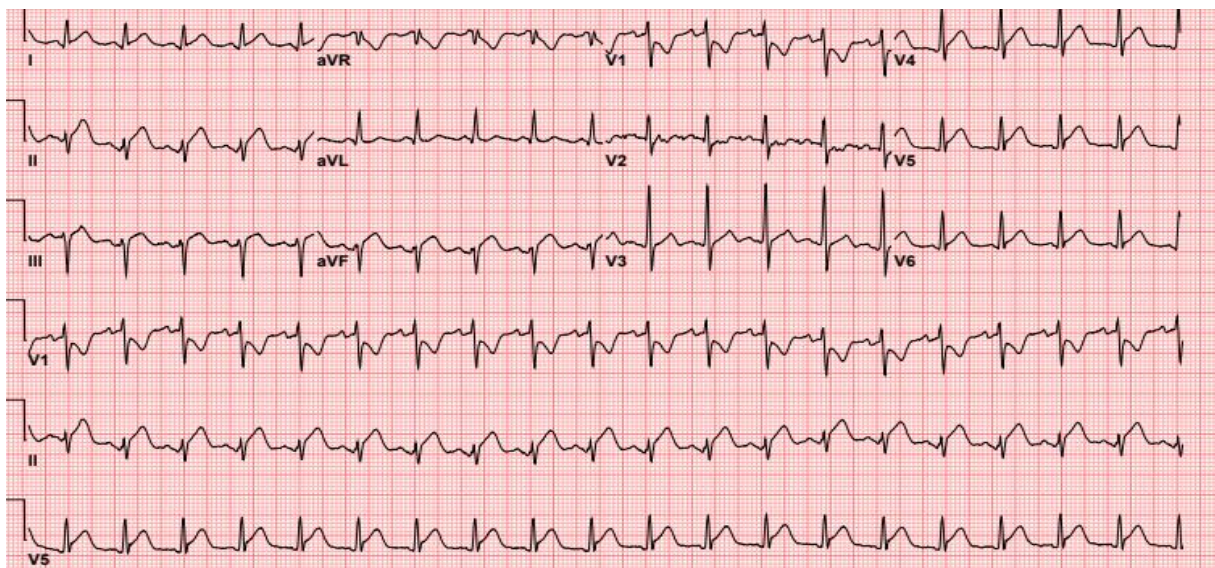
Patient #11



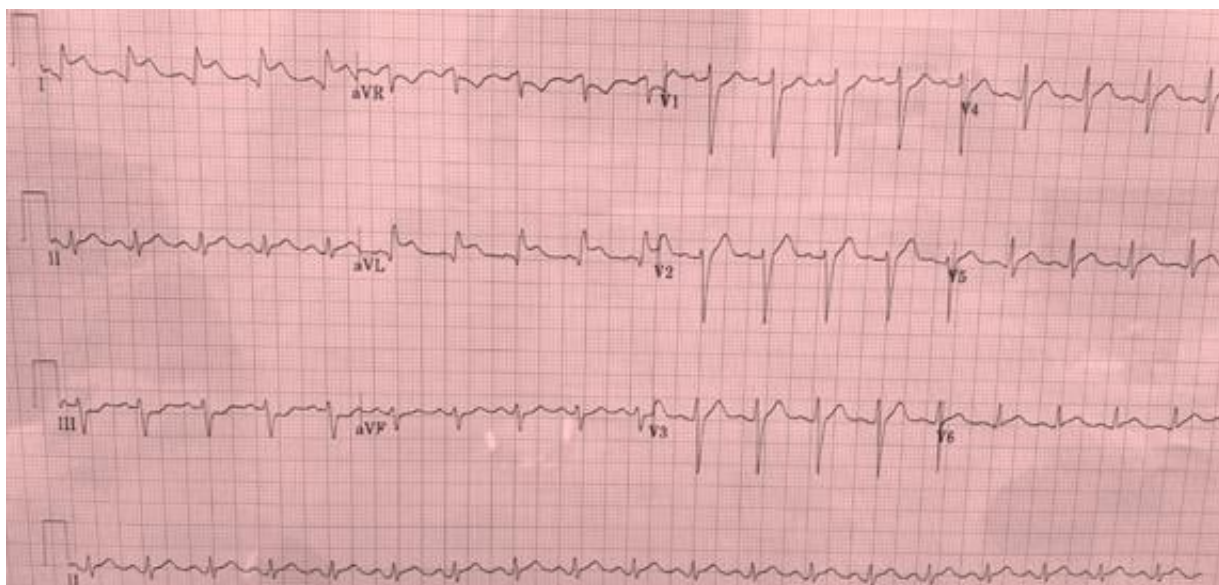Patient #12



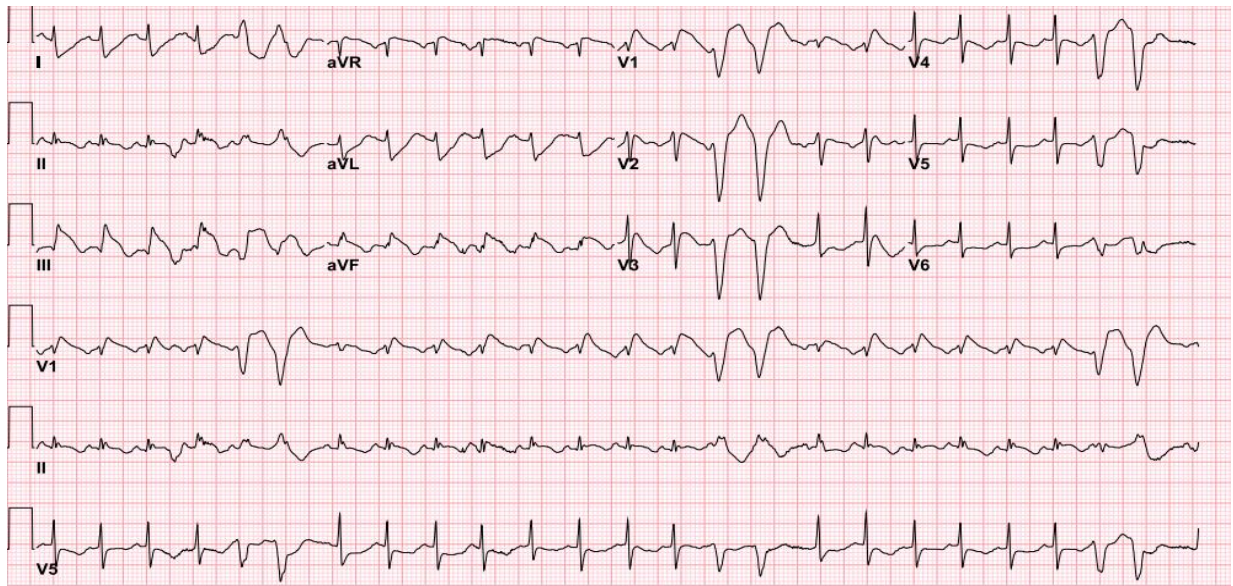
Patient #13



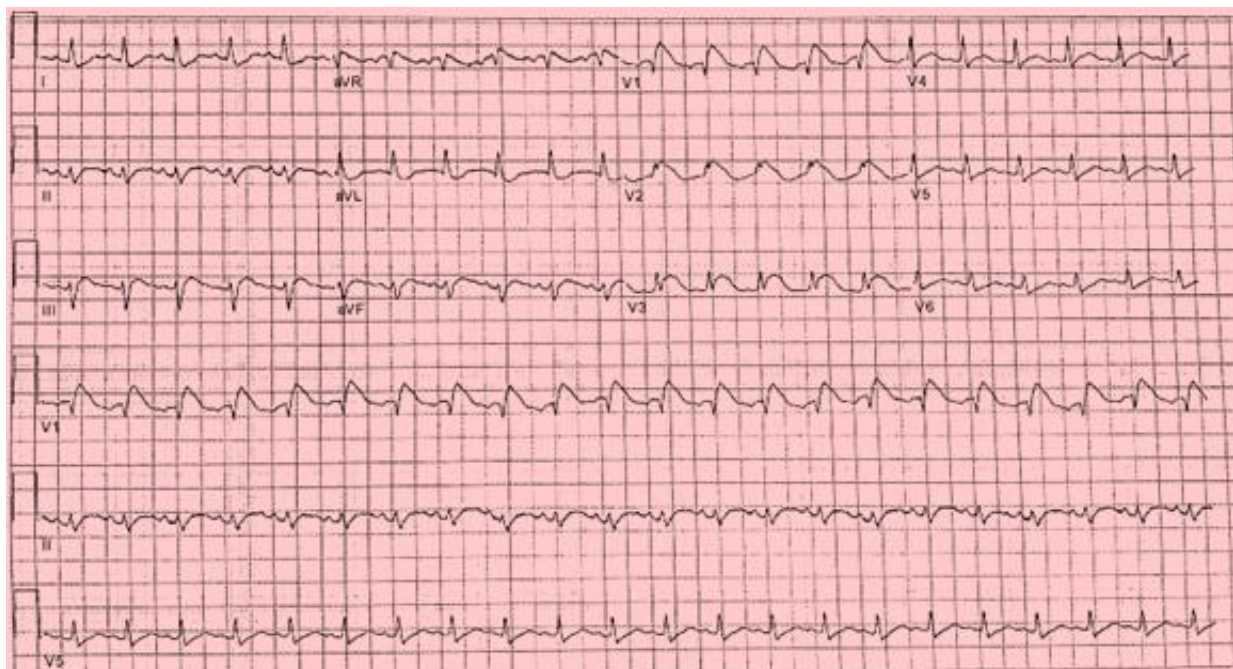
Patient #14



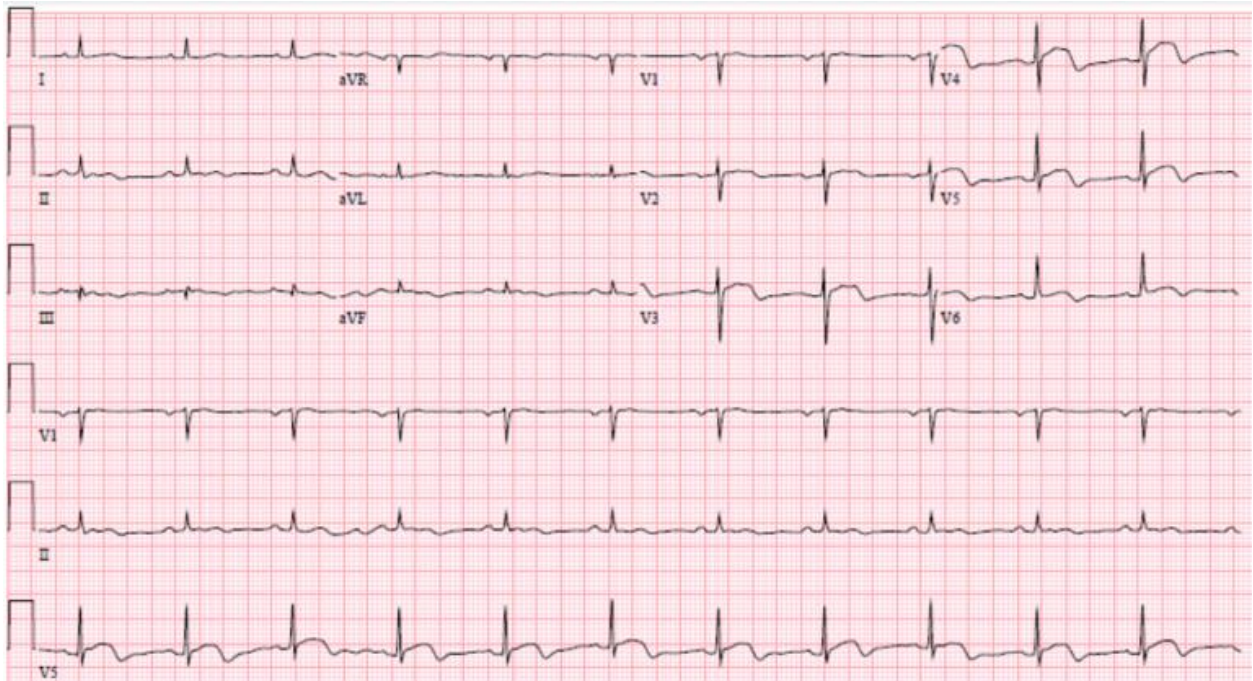
Patient #15



Patient #16



Patient #17



Patient #18

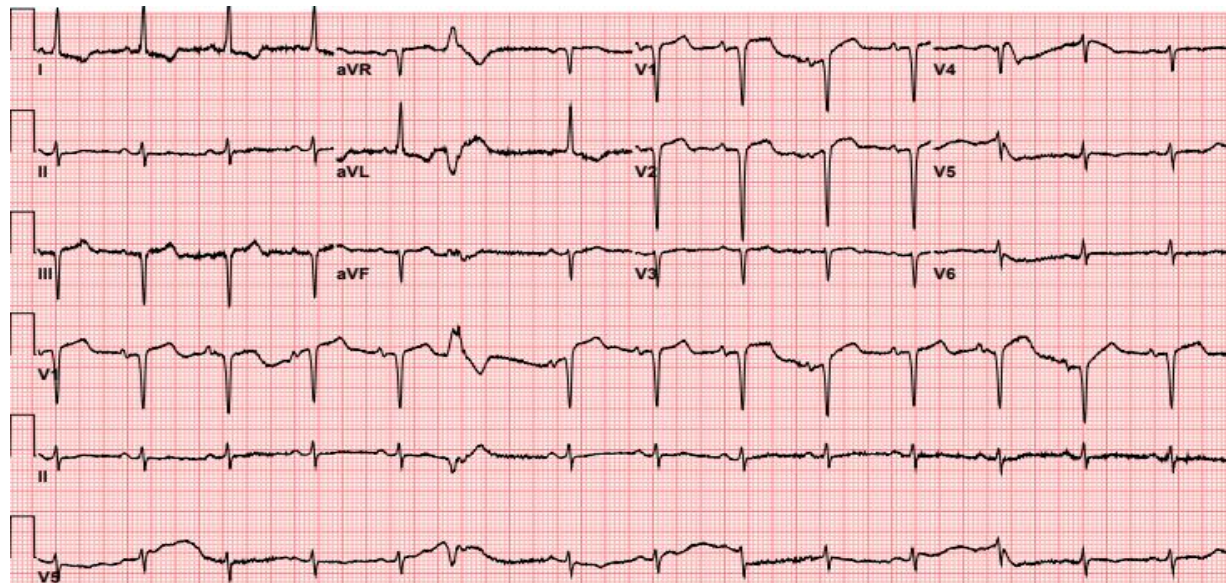
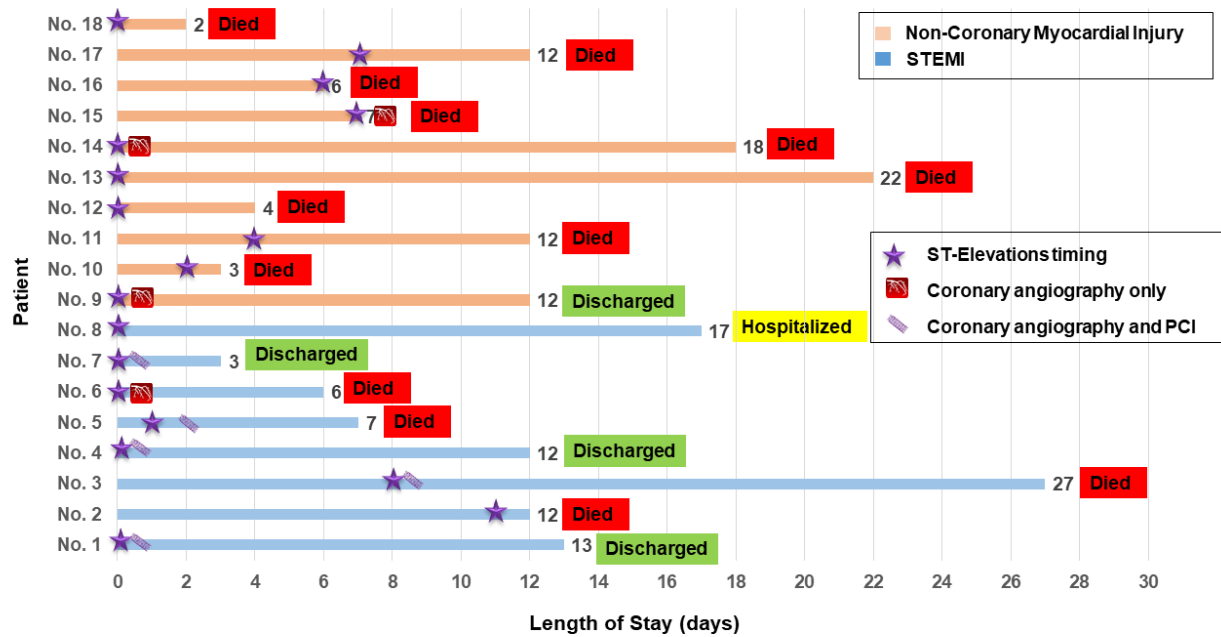
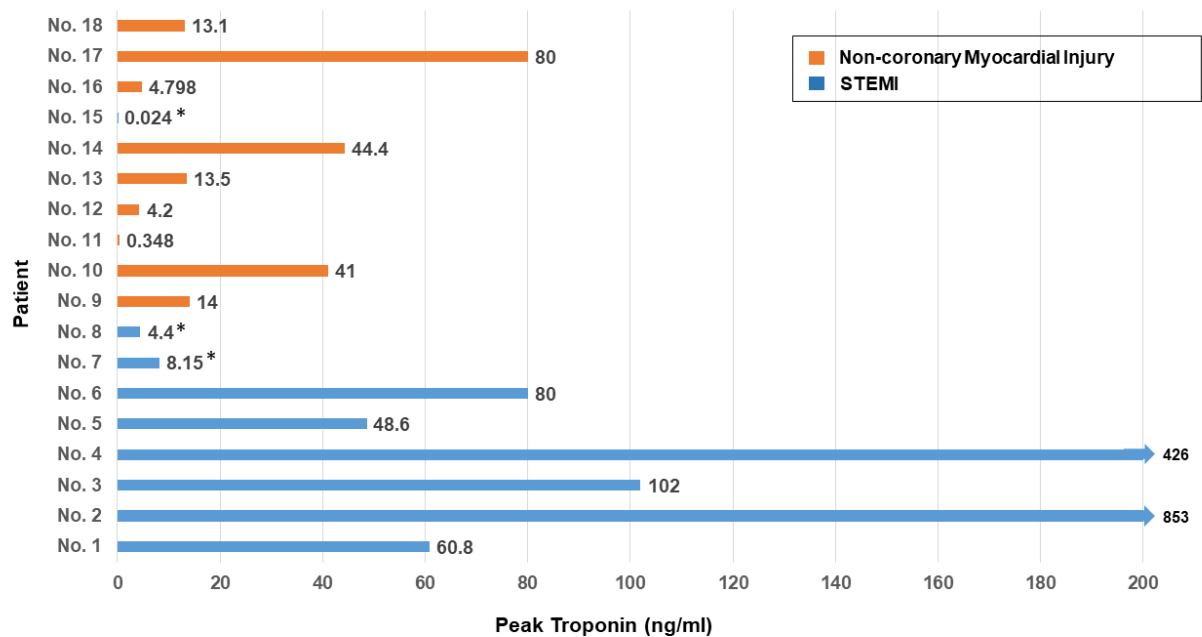


Figure S2A. Timing of ST-segment elevation, length of stay and outcome



Please note, coronary angiography with or without PCI was at the time of ST-elevations (except patient 5). Patient #5 received thrombolytic therapy at the time of ST-segment elevation and underwent PCI a day later. Patient #6 had obstructive CAD with heavy thrombus burden which was managed with anticoagulation without PCI.

Figure S2B. Peak troponin levels



*Troponin-T (ref ≤0.01 ng/ml). Rest of the assay were Troponin-I (ref ≤0.06 ng/ml)

Figure S2C. D-dimer levels

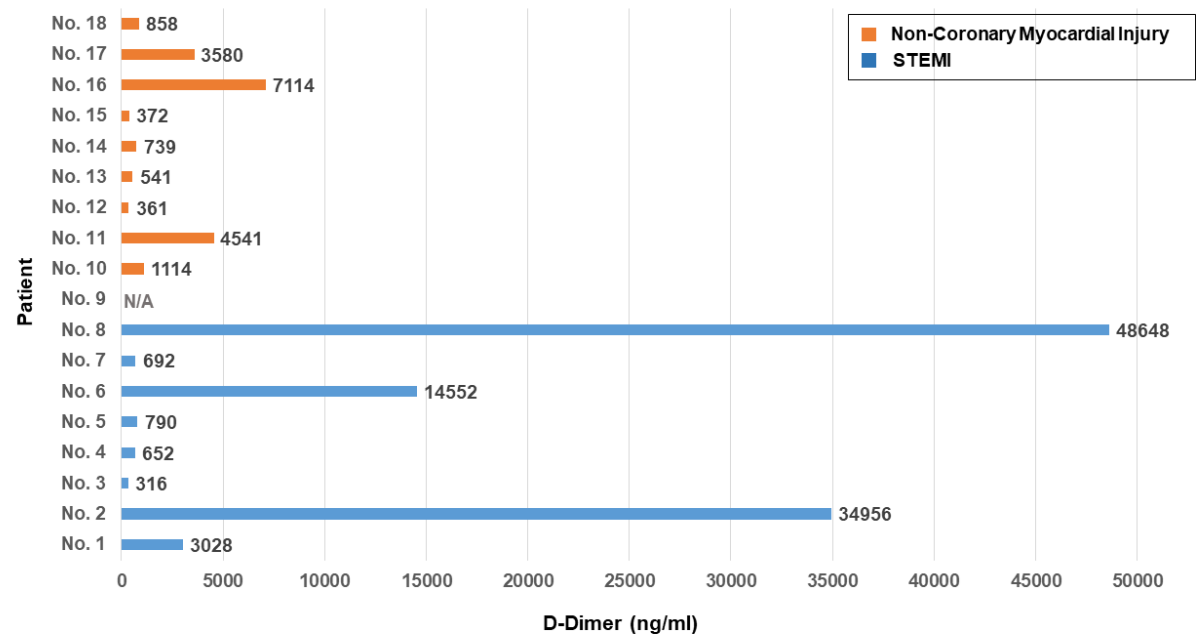
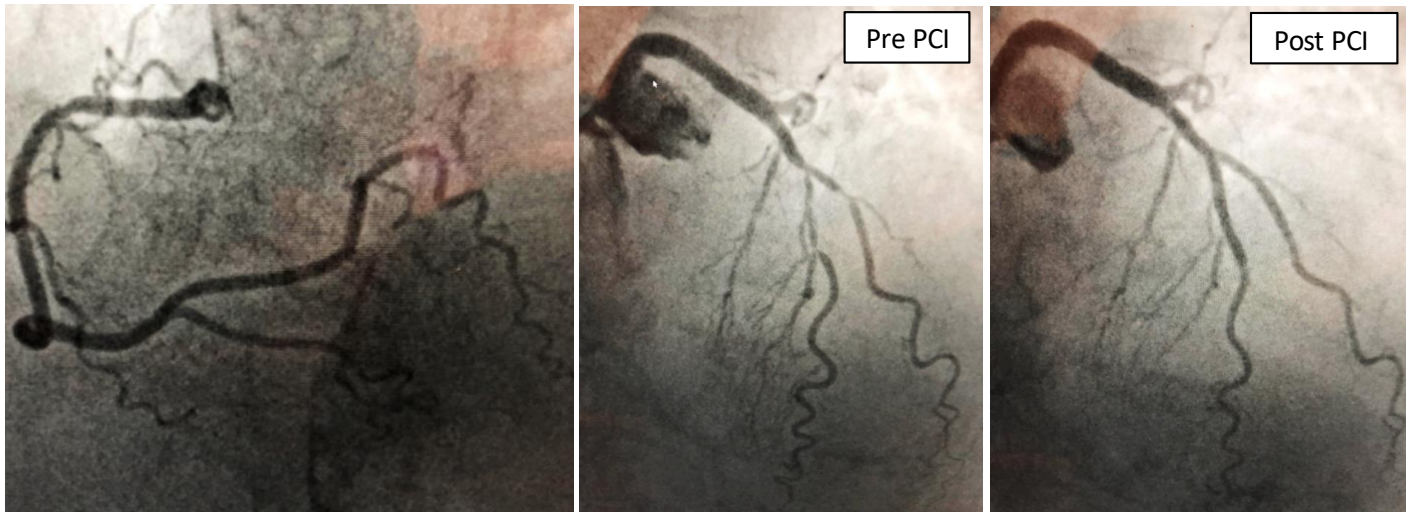
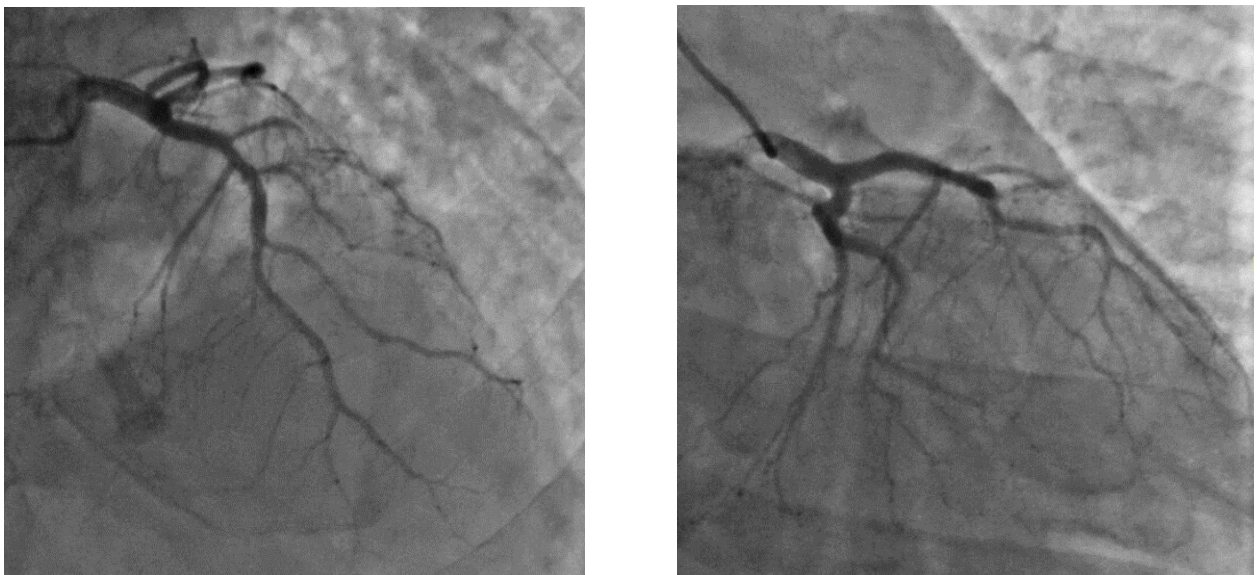


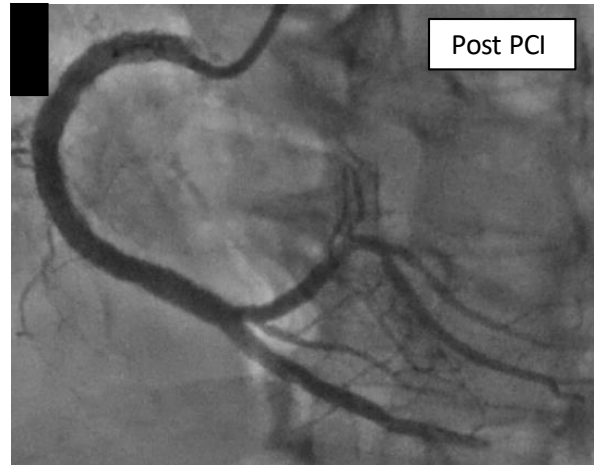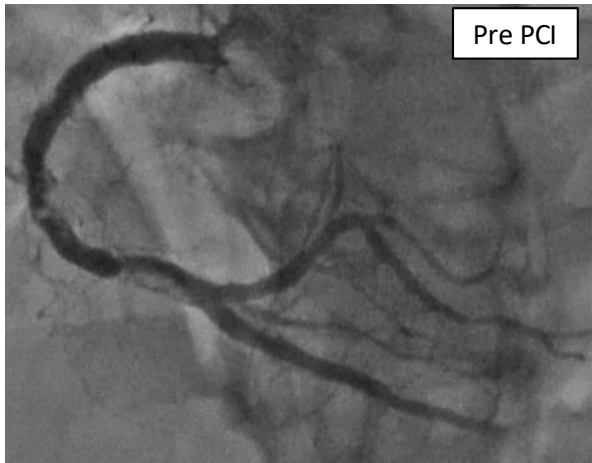
Figure S3. Coronary angiography

Patient #1

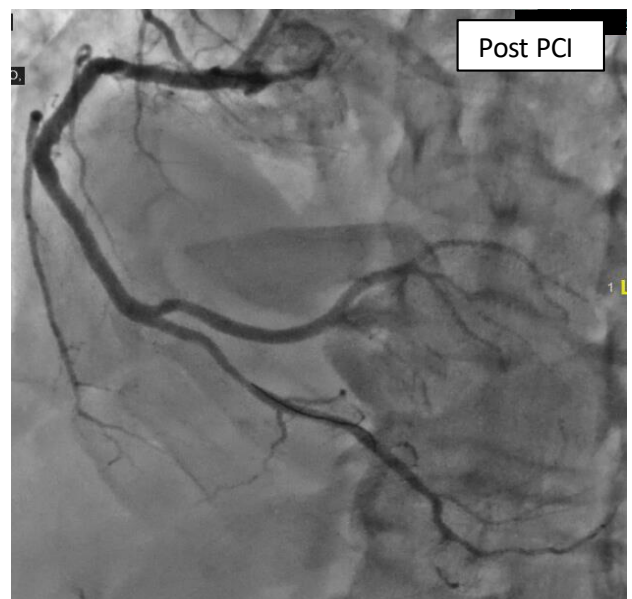
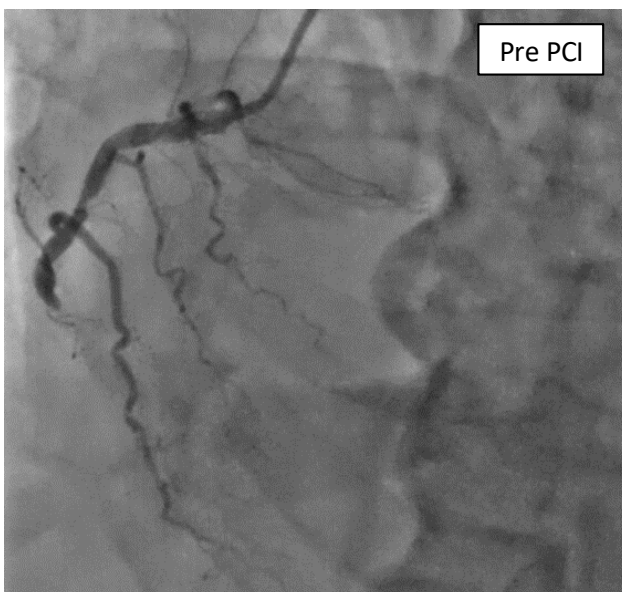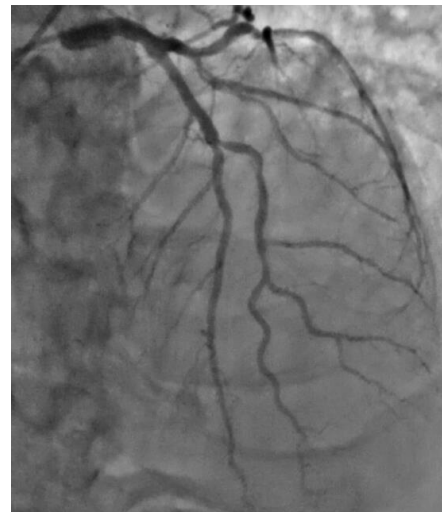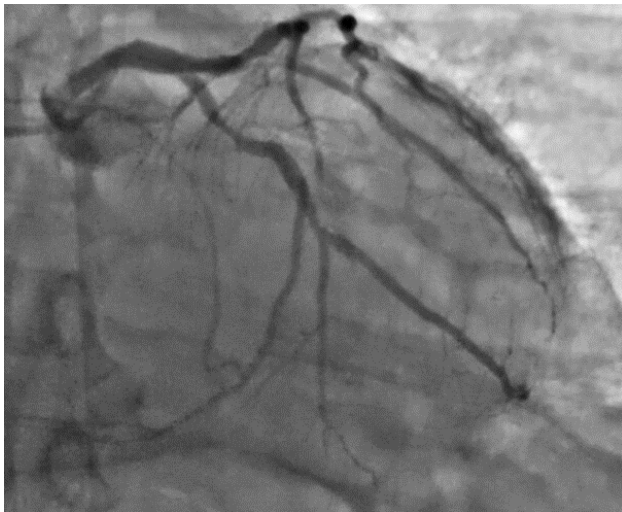


Patient #3

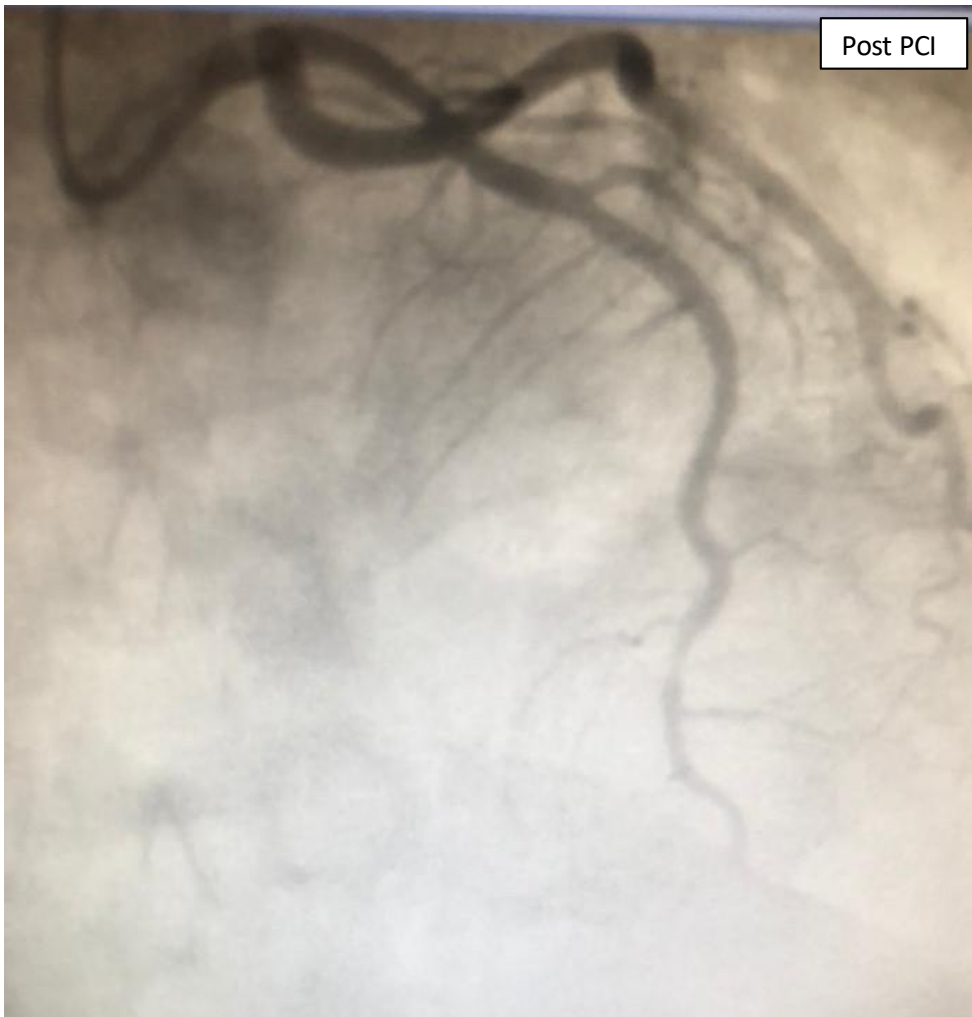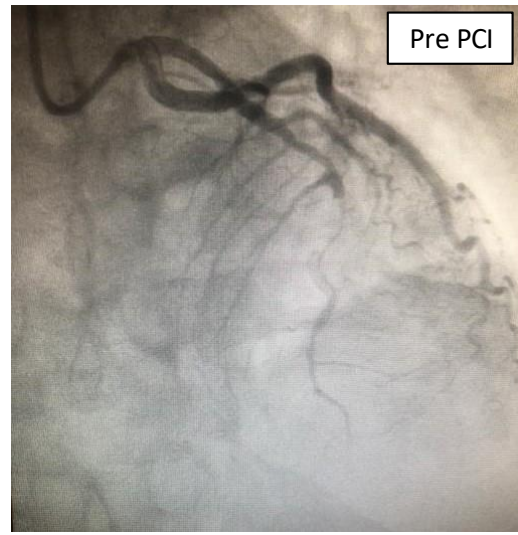
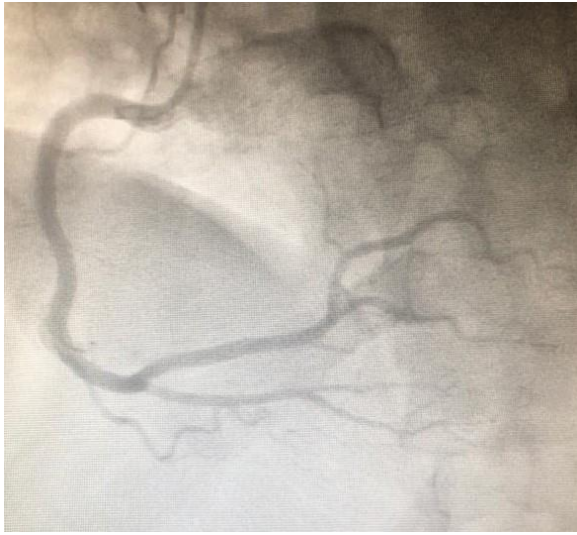




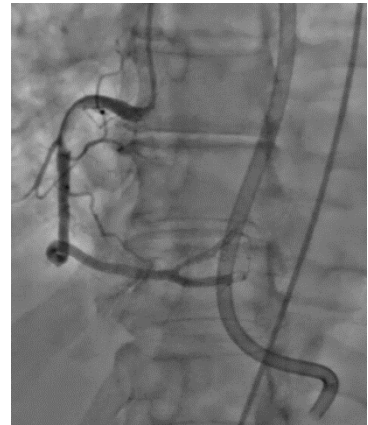
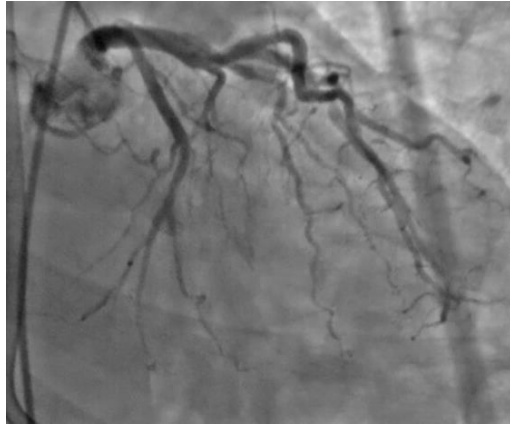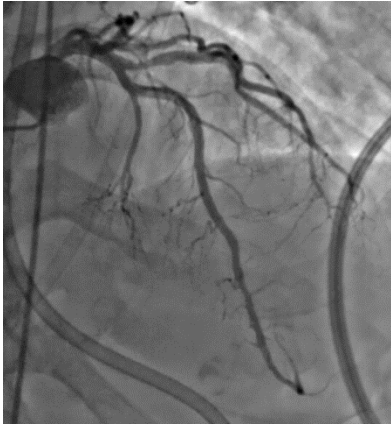Patient #4



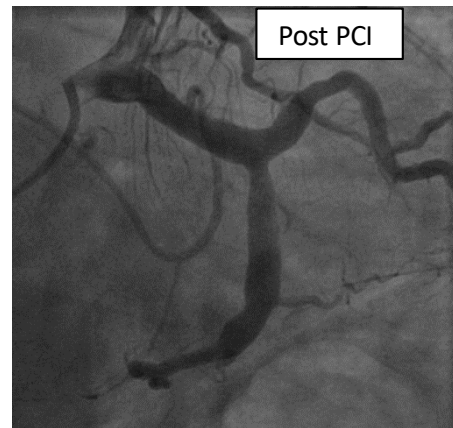
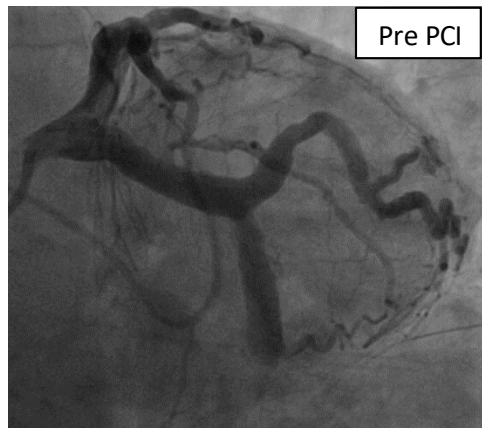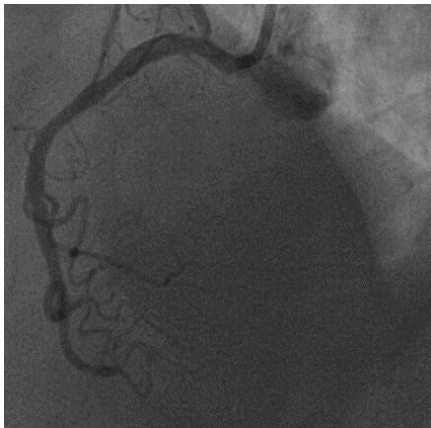
Patient #5



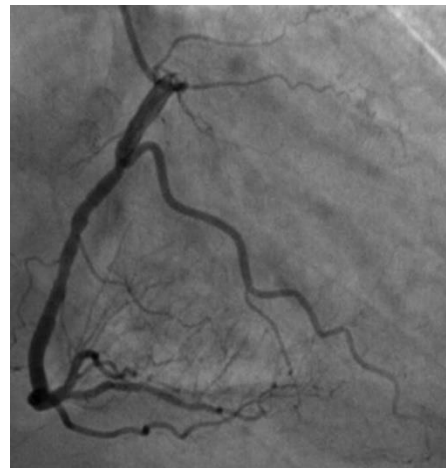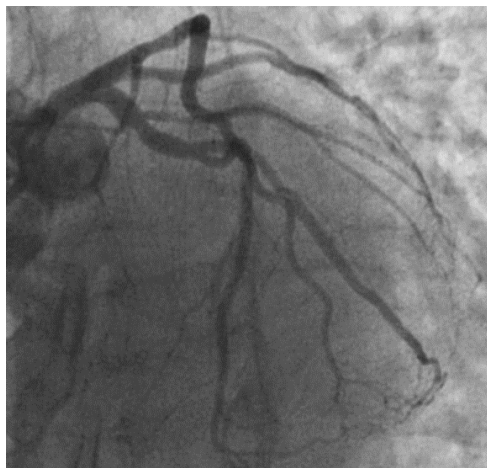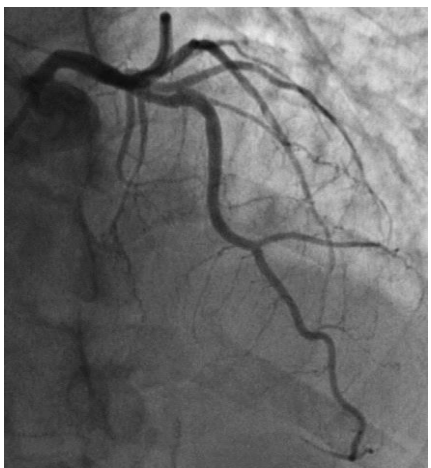Patient #6



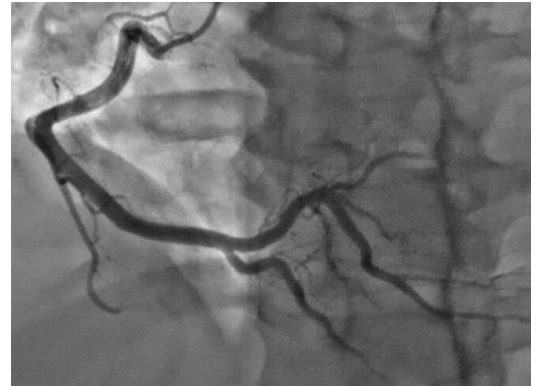
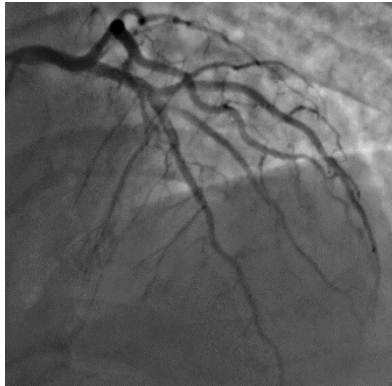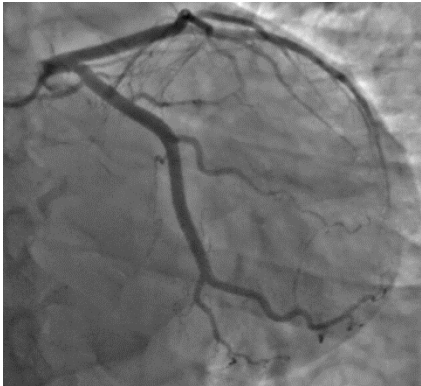Patient #7



Patient #9



Patient #14



Patient #15

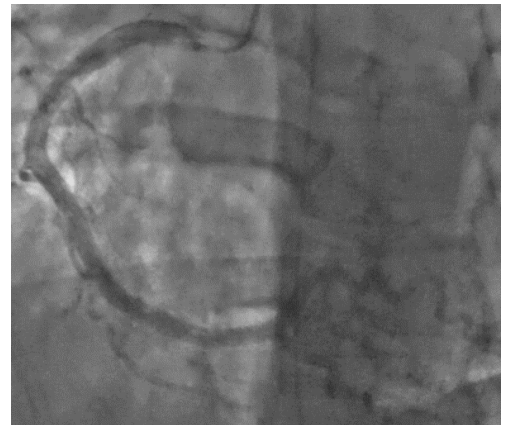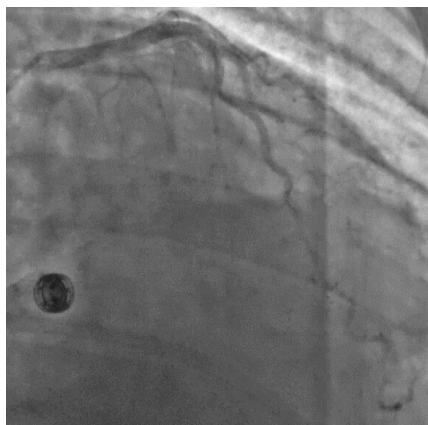
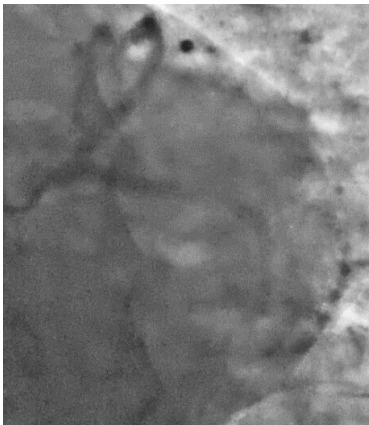


Figure S4. Electrocardiogram, echocardiogram and coronary angiography

