

BRIEF REPORT

Isolation of a Novel Coronavirus from a Man with Pneumonia in Saudi Arabia

Ali Moh Zaki, M.D., Ph.D., Sander van Boheemen, M.Sc., Theo M. Bestebroer, B.Sc.,
Albert D.M.E. Osterhaus, D.V.M., Ph.D., and Ron A.M. Fouchier, Ph.D.

SUMMARY

A previously unknown coronavirus was isolated from the sputum of a 60-year-old man who presented with acute pneumonia and subsequent renal failure with a fatal outcome in Saudi Arabia. The virus (called HCoV-EMC) replicated readily in cell culture, producing cytopathic effects of rounding, detachment, and syncytium formation. The virus represents a novel betacoronavirus species. The closest known relatives are bat coronaviruses HKU4 and HKU5. Here, the clinical data, virus isolation, and molecular identification are presented. The clinical picture was remarkably similar to that of the severe acute respiratory syndrome (SARS) outbreak in 2003 and reminds us that animal coronaviruses can cause severe disease in humans.

From the Dr. Soliman Fakeeh Hospital, Jeddah, Saudi Arabia (A.M.Z.); and the Viroscience Lab, Erasmus Medical Center, Rotterdam, the Netherlands (S.B., T.M.B., A.D.M.E.O., R.A.M.F.). Address reprint requests to Dr. Fouchier at the Department of Viroscience, Erasmus Medical Center, Dr. Molewaterplein 50, 3015GE Rotterdam, the Netherlands, or at r.fouchier@erasmusmc.nl.

This article was published on October 17, 2012, and updated on July 3, 2013, at NEJM.org.

N Engl J Med 2012;367:1814-20.

DOI: 10.1056/NEJMoa1211721

Copyright © 2012 Massachusetts Medical Society.

CORONAVIRUSES ARE ENVELOPED, SINGLE-STRANDED, POSITIVE-SENSE RNA viruses that are phenotypically and genotypically diverse.¹ Coronaviruses are widespread in bats around the world but can be found in many other species as well, including birds, cats, dogs, pigs, mice, horses, whales, and humans.¹ They may cause respiratory, enteric, hepatic, or neurologic diseases, with variable severity in various animal species. In humans, four respiratory coronaviruses — human coronaviruses (HCoV) 229E, OC43, NL63, and HKU1 — are known to be endemic. In addition, in 2003 a previously unknown coronavirus caused an outbreak of SARS in humans.²⁻⁴ The diversity of coronaviruses is facilitated by the infidelity of the RNA-dependent RNA polymerase, the high frequency of RNA recombination, and the unusually large genomes for RNA viruses.^{1,5} These factors not only have led to the diversity of known coronaviruses but also have facilitated the emergence of viruses with new traits that allow the organism to adapt to new hosts and ecologic niches, sometimes causing zoonotic events.

CASE REPORT

A 60-year-old Saudi man was admitted to a private hospital in Jeddah, Saudi Arabia, on June 13, 2012, with a 7-day history of fever, cough, expectoration, and shortness of breath. He had no history of cardiopulmonary or renal disease, was receiving no long-term medications, and did not smoke. The physical examination revealed a body-mass index (the weight in kilograms divided by the square of the height in meters) of 35.1, a blood pressure of 140/80 mm Hg, a pulse of 117 beats per minute, a temperature of 38.3°C, and a respiratory rate of 20 breaths per minute.

Chest radiography performed on admission showed low lung volumes, bilateral enhanced pulmonary hilar vascular shadows more prominent on the left, and accentuated bronchovascular lung markings. Multiple segmental, patchy, veiling

opacities were present in the middle and lower lung fields; the costophrenic angles were not blunted. The cardiac silhouette was not enlarged, with a dilated, unfolded aorta (Fig. 1A, and images in the Supplementary Appendix, available with the full text of this article at NEJM.org). On chest radiography performed 2 days later, the opacities had become more confluent and dense (Fig. 1B). Computed tomography performed 4 days after admission revealed few subcentimetric mediastinal hilar lymph nodes, bilateral dependent airspace opacities with air bronchograms, scattered areas of ground-glass opacity, interstitial septal thickening, and nodularity in upper lobes, with minimal bilateral pleural effusions and no pericardial pleural effusion (Fig. 1C). Collectively, these findings were consistent with an infection.

On day 1, treatment was started with oseltamivir, levofloxacin, piperacillin–tazobactam, and micafungin. On day 4, treatment with meropenem was started, since *Klebsiella pneumoniae* that was sensitive to meropenem was detected on bronchoscopy and tracheal lavage performed on day 2. *Staphylococcus aureus*, which was sensitive to a wide range of antimicrobials, was collected from a sputum sample collected on admission. *Acinetobacter* was detected in a tracheal aspirate sample collected on the day of death. No other pathogens were detected in respiratory specimens, and no bacterial growth was detected from blood samples.

On the day after admission, the patient was transferred to an intensive care unit, where he underwent intubation for mechanical ventilation. Laboratory findings obtained on admission showed normal white-cell counts, except for a relatively high percentage of neutrophils (92.5%) and a low percentage of lymphocytes (4.3%) (Table 1). Levels of liver enzymes, blood urea nitrogen, and creatinine were within the normal ranges. Somewhat elevated liver enzymes were detected on day 7 and later, with levels of alanine aminotransferase of 20 IU, 78 IU, and 47 IU per liter on days 1, 7, and 8, and levels of aspartate aminotransferase of 33 IU and 96 IU per liter on days 1 and 8, respectively. The patient tested negative for the human immunodeficiency virus; testing was not performed for pneumocystis pneumonia.

Starting on day 3 after admission, levels of blood urea nitrogen and creatinine progressively increased. Starting on day 8, the white-cell count

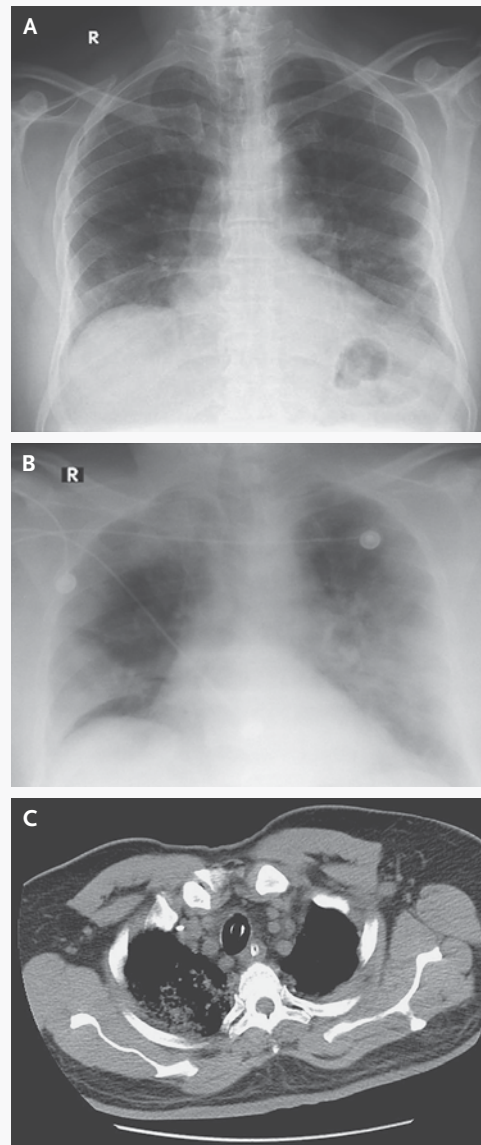


Figure 1. Abnormalities on Chest Imaging of the Patient.

Shown are chest radiographs of the patient on the day of admission (Panel A) and 2 days later (Panel B) and computed tomography (CT) 4 days after admission (Panel C). Additional chest radiographs and CT images are provided in the Supplementary Appendix.

began to rise, reaching a peak of 23,800 cells per cubic millimeter on day 10, with neutrophilia, persistent lymphopenia, and progressive thrombocytopenia. Arterial oxygen saturation ranged from 78 to 98% (Table 1). On day 11 after admission (June 24, 2012), the patient died of progres-

Table 1. Laboratory Data for the Patient.*

Hospital Day after Admission	White Cells	Neutrophils	Lymphocytes	Platelets	Blood Urea Nitrogen	Creatinine	Arterial Oxygen Saturation†
		<i>cells/mm³</i>				<i>mg/dl</i>	%
Day 0	9,300	8,600	400	168,000	NA	0.9	NA
Day 1	8,900	7,900	600	157,000	NA	NA	NA
Day 2	8,600	7,500	600	163,000	14.2	1.1	85.0
Day 3	9,600	8,600	600	149,000	27.2	2.1	84.8
Day 4	6,700	6,100	500	148,000	61.9	5.1	93.3
Day 5	8,400	7,500	400	171,000	98.1	7.8	98.8
Day 6	NA	NA	NA	NA	104	8.8	NA
Day 7	8,600	8,200	300	156,000	NA	9.7	78.1
Day 8	11,800	11,200	400	112,000	116	7.9	91.5
Day 9	21,000	20,100	400	85,000	94	7.3	83.7
Day 10	23,800	22,800	300	78,000	121	9.6	92.1
Day 11	22,400	21,300	500	69,000	123	7.3	87.0

* Reference ranges are as follows: white-cell count, 4×10^3 to 10×10^3 per cubic millimeter; neutrophil count, 2×10^3 to 7×10^3 per cubic millimeter; lymphocyte count, 1×10^3 to 4×10^3 per cubic millimeter; platelets, 140×10^3 to 400×10^3 per cubic millimeter; blood urea nitrogen, 8 to 26 mg per deciliter; creatinine, 0.7 to 1.2 mg per deciliter; and arterial oxygen saturation, 95 to 100%. To convert the values for blood urea nitrogen to millimoles per liter, multiply by 0.357. To convert the values for creatinine to micromoles per liter, multiply by 88.4. NA denotes not available.

† All values for arterial oxygen saturation were obtained with the patient breathing supplemental oxygen; the exact values for the fraction of inspired oxygen are not known.

sive respiratory and renal failure. A postmortem examination was not performed.

METHODS

CLINICAL SPECIMENS AND VIRAL CULTURE

Blood samples were collected in vacutainers with and without EDTA. Sputum samples were collected in sterile cups, after which virus transport medium was added; samples were stirred and centrifuged at 2000 rpm for 10 minutes. Supernatant was transferred to a new sterile tube and used to inoculate Vero and LLC-MK2 cells by adsorption for 1 hour at room temperature, after which 2% fetal bovine serum in minimal essential medium Eagle was added. Flasks were incubated in a carbon dioxide incubator at 37°C and observed daily for 15 days for cytopathic changes with change of medium every 3 days.

VIRAL DIAGNOSTICS

Respiratory epithelial cells from sputum were washed three times in phosphate-buffered saline (PBS), resuspended in 1 ml of PBS, and spotted on Teflon-coated slides. Slides were left to air-dry

and then fixed for 10 minutes in chilled acetone. Slides were tested by indirect immunofluorescence for influenza A virus, influenza B virus, parainfluenza viruses types 1 to 3, adenovirus, and respiratory syncytial virus with the use of a Bartels Viral Respiratory Screening and Identification Kit, as described by the manufacturer (Trinity Biotech). The same procedure was used to detect viral antigens in inoculated cells after cytopathic effects had been observed. To this end, cells were scraped from tissue-culture flasks, and cells with media were transferred to a sterile centrifuge tube and prepared as described for respiratory epithelial cells from sputum. Supernatant from sputum as well as from experimentally inoculated cell cultures that displayed cytopathic effects (and uninfected cultures as negative controls) was extracted with the use of a High Pure Viral Nucleic Acid Kit, as described by the manufacturer (Roche). Extracted nucleic acids were tested by reverse-transcriptase–polymerase-chain-reaction (RT-PCR) assay designed to detect all known paramyxoviruses,^{6,7} coronaviruses,^{3,8} and enteroviruses⁹ and by real-time PCR for adenoviruses.¹⁰

VIRAL GENOME SEQUENCING

To sequence the PCR fragments of the pan-coronavirus PCR,³ amplicons were purified from the gel and sequenced with the use of a BigDye Terminator v3.1 Cycle Sequencing Kit (Applied Biosystems) and a 3130XL Genetic Analyzer (Applied Biosystems), according to the manufacturer's instructions. To further characterize the virus genome, we used a random-amplification deep-sequencing approach. Supernatant was cleared from cellular debris by low-speed centrifugation, and virus was filtered through a 0.45- μ m centrifugal filter unit (Millipore) to minimize bacterial background. We used OmniCleave endonuclease (Epicenter) to remove free DNA and RNA, according to the manufacturer's protocol. Viral RNA was extracted from supernatants in infected cell cultures with the use of a High Pure RNA Isolation Kit (Roche). To remove mammalian ribosomal RNA, we used Ribo-Zero rRNA Removal Kit RZH110424 (Epicenter), according to the manufacturer's protocol. RNA underwent reverse transcription with the use of circular permuted primers¹¹ that were extended with random hexamer sequences. DNA was amplified by means of PCR with the circular permuted primers.

We sequenced the amplified fragments using the Roche 454 GS FLX sequencing platform. A fragment library was created according to the manufacturer's protocol without DNA fragmentation (GS FLX Titanium Rapid Library Preparation, Roche). The emulsion-based clonal amplification PCR (Amplification Method Lib-L) and GS junior sequencing run was performed according to the manufacturer's instructions (Roche). The sequence reads were trimmed at 30 nucleotides from the 3' and 5' ends to remove all primer sequences. Sequence reads from the GS FLX sequencing data were assembled into contig maps (a set of overlapping DNA segments) with the use of CLC Genomics software, version 4.6.1 (CLC Bio). Using the 454 sequencing platform, we obtained approximately 90% of the virus genome sequence. Subsequently, specific primers were designed to amplify overlapping fragments of approximately 800 bp by means of PCR. These PCR products were purified from the gel and sequenced with the use of a BigDye Terminator v3.1 Cycle Sequencing Kit and a 3130XL Genetic Analyzer, according to the manufacturer's instructions.

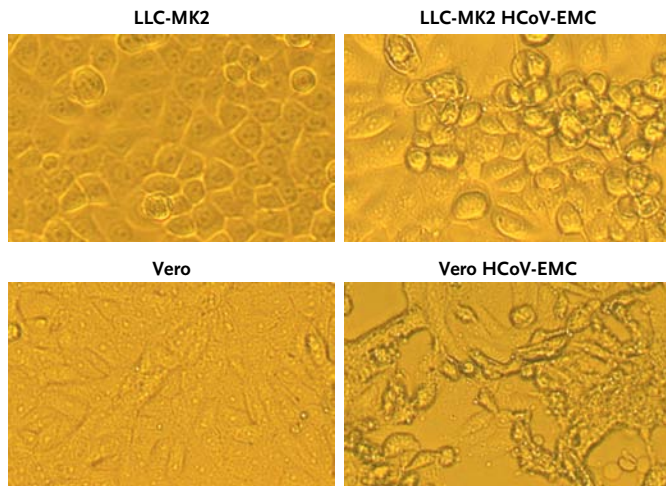
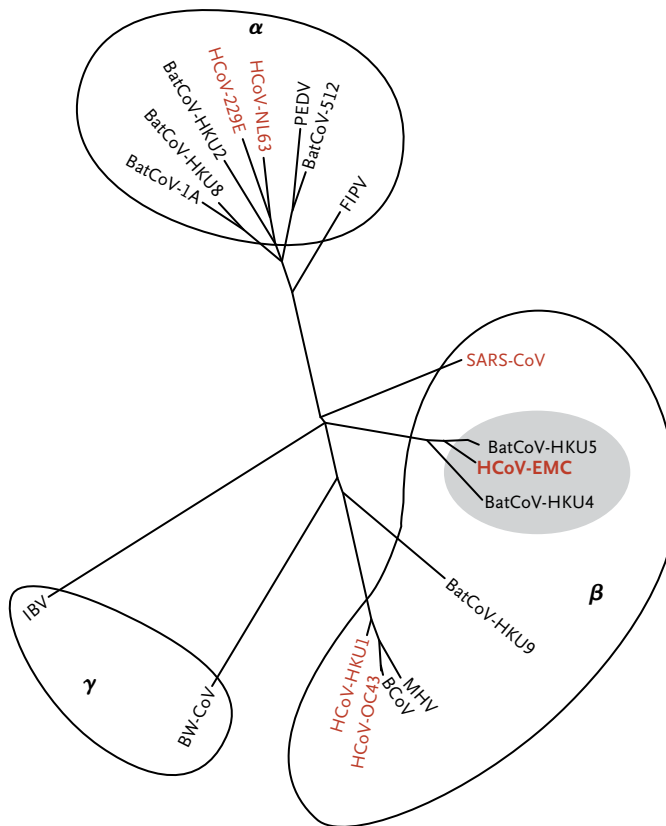
RESULTS

DETECTION OF A CORONAVIRUS

The day 1 sputum sample tested negative by indirect immunofluorescence assays for influenza A and B viruses, parainfluenza viruses types 1 to 3, respiratory syncytial virus, and adenovirus. However, for a sputum sample obtained on admission, inoculation in LLC-MK2 and Vero cells resulted in cytopathic changes suggestive of virus replication (Fig. 2A). Cytopathic changes consisted of syncytium formation in LLC-MK2 cells at low pH and rounding and detachment of cells at neutral or alkaline pH in Vero and LLC-MK2 cells. On passage of the culture supernatant to fresh cells, the same cytopathic effects were observed within 5 days. Virus was not isolated from a blood sample collected on admission or from a tracheal aspirate sample collected 4 days after admission.

Indirect immunofluorescence assays for the detection of influenza A and B viruses, parainfluenza viruses types 1 to 3, respiratory syncytial virus, and adenovirus were performed with the infected cell cultures, but again with negative results. In contrast, when these slides were incubated with serum samples collected from the patient 10 and 11 days after admission, the samples reacted strongly when dilutions of 1:20 were tested on immunofluorescence assay specific for IgG antibodies. No attempts were made to detect virus-specific IgM antibodies. In contrast, 2400 control serum samples collected from persons seeking medical attention at the Dr. Soliman Fakeeh Hospital in Jeddah from 2010 through 2012 remained negative in this assay. These data suggested that antibodies to an unknown virus had developed in the patient, although such antibodies were not detectable in the general population over the previous 2 years.

Real-time PCR assays specific for adenovirus, enterovirus, human metapneumovirus, and human herpesvirus types 1 to 3 yielded negative results with the use of nucleic acids extracted from the inoculated cell-culture supernatants. Furthermore, family-wide PCR assays that can detect all known paramyxoviruses^{6,7} also yielded negative results. However, family-wide PCR assays for the detection of coronaviruses^{3,8} yielded PCR fragments of the expected sizes.

A Cytopathic Effects**B Phylogenetic Tree****GENETIC ANALYSIS OF A NOVEL CORONAVIRUS**

The PCR fragments of the pan-coronavirus PCR³ were sequenced. This sequence corresponded with a conserved region of open reading frame 1b of the replicase gene of a coronavirus. Reference coro-

Figure 2. Cytopathic Effects and a Phylogenetic Tree of the Novel Coronavirus.

Panel A shows cytopathic effects in LLC-MK2 and Vero cell cultures after inoculation with the novel coronavirus HCoV-EMC. Panel B shows the genetic relationship between HCoV-EMC and other coronaviruses in a maximum-likelihood phylogenetic tree. The tree is based on a 408-nucleotide fragment of the open reading frame 1b. The following viruses and accession numbers were used: feline infectious peritonitis virus (FCoV; NC007025), HCoV-229E (NC002645), porcine epidemic diarrhea virus (PEDV; NC003436), HCoV-NL63 (DQ445911), BatCoV-1A (NC010437), BatCoV-HKU8 (NC010438), BatCoV-HKU2 (NC009988), BatCoV-512 (DQ648858), bovine coronavirus (BCoV; NC003045), HCoV-OC43 (AY585228), HCoV-HKU1 (AY884001), murine hepatitis virus (MHV; NC006852), BatCoV-HKU5 (EF065509), BatCoV-HKU9 (EF065513), SARS-CoV (AY345988), BatCoV-HKU4 (EF065505), avian infectious bronchitis virus (IBV; NC001451), Beluga whale coronavirus (BWCoV; EU111742), and HCoV-EMC (JX869059). Alpha, beta, and gamma denote genera in the Coronavirinae subfamily. The five other coronaviruses that have been detected in humans are indicated in red. Lineage C of the betacoronavirus genus containing HCoV-EMC is shaded in gray.

navirus genome sequences were downloaded from GenBank and aligned with the amplified fragment of the newly discovered virus, hereafter called HCoV-EMC (for Erasmus Medical Center). A maximum-likelihood tree was constructed to infer the phylogenetic relationships (Fig. 2B). This phylogenetic tree showed that HCoV-EMC belonged to lineage C of the genus betacoronavirus, along with the bat coronaviruses HKU4 and HKU5. The betacoronavirus genus contains three additional lineages; A, B, and D.¹ HCoV-HKU1 and HCoV-OC43 belong to lineage A, whereas SARS-CoV belongs to lineage B. Lineage D does not contain any human pathogens and is represented in the tree by Rousettus bat coronavirus HKU9. Thus, HCoV-EMC is distinct from previously known human coronaviruses. HCoV-NL63 and HCoV-229E are even more distinct from HCoV-EMC, since these two human pathogens belong to a different genus, alphacoronavirus (Fig. 2B).

To further characterize the virus, approximately 90% of the virus genome sequence was obtained on sequence analysis with the use of the 454 platform. Subsequently, specific primers were designed to amplify overlapping PCR fragments of approximately 800 bp each for conventional Sanger sequencing. The nearly full-length sequence was obtained (GenBank accession number, JX869059),

for which final annotation remained in progress at the time of this report. The HCoV-EMC virus genome encodes the open reading frames common to betacoronaviruses, including open reading frame 1ab, which encodes many enzymatic products, the spike-surface glycoprotein (S), the small-envelope (E) protein, the matrix (M) protein, and the nucleocapsid (N) protein, as well as several nonstructural genes. The genome does not encode a hemagglutinin-esterase protein, in contrast to some other betacoronaviruses.

We compared the open reading frame 1ab gene product of HCoV-EMC with those of the other betacoronaviruses, HKU4 and HKU5, to test whether HCoV-EMC might belong to one of these known species or whether it represents a new species within the genus. The International Committee on Taxonomy of Viruses (ICTV) considers that viruses sharing more than 90% of sequence identity in the conserved replicase domains belong to the same species.¹ This 90% identity threshold serves as the sole species demarcation criterion. Since the identity of amino acid sequences in these conserved domains of open reading frame 1ab between HCoV-EMC and HKU4 and HKU5 was less than 80%, we concluded that HCoV-EMC represented a novel betacoronavirus species, although such classification requires formal ICTV approval.

DISCUSSION

The first decade of the 21st century has witnessed an increase in the number of coronaviruses that have been identified, along with a corresponding increase in the number of coronavirus genomes that have been sequenced. Such increases were due to the discovery of the SARS coronavirus, which resulted in a global outbreak of pneumonia in 2003 that affected persons in approximately 30 countries and resulted in about 800 deaths.¹² Before 2003, only two human coronaviruses were known, HCoV-229E and HCoV-OC43, both discovered in the 1960s.^{13,14} After the emergence of the SARS-CoV in 2003, two additional human coronaviruses were discovered, HCoV-NL63 and HCoV-HKU1.¹⁵⁻¹⁷ Here we report the isolation and characterization of the sixth coronavirus that apparently may infect humans.

On the basis of genetic data, the ICTV has identified four virus clusters within the Coronavirinae subfamily, of which three represent ap-

proved genera; alphacoronavirus, betacoronavirus, and gammacoronavirus. The five known human coronaviruses all belong to the genera alphacoronavirus (HCoV-229E and HCoV-NL63) and betacoronavirus (HCoV-OC43, HCoV-HKU1, and SARS-CoV).^{2-4,13-16,18} HCoV-EMC is the first human coronavirus in lineage C of the betacoronavirus genus. Its closest relatives are coronaviruses HKU4 and HKU5, isolated from *Tylonycteris pachypus* and *Pipistrellus abramus* bats, respectively.¹⁷

As compared with other coronaviruses, HCoV-EMC was isolated and propagated relatively easily in Vero and LLC-MK2 cells. The only other human coronaviruses that replicate well in these monkey-cell lines are SARS-CoV and HCoV-NL63, which both use human angiotensin-converting enzyme 2 as their receptor. We hypothesize that one or more species of animals, possibly bats, were the reservoir host of this new coronavirus. Saudi Arabia harbors numerous bat species, including pipistrellus bats, which were found to carry BatCoV-HKU5 in Asia.

The patient's findings on chest radiography together with the clinical symptoms indicated acute respiratory distress syndrome (ARDS) with multiorgan dysfunction syndrome (MODS), similar to what has been described in severe cases of influenza and SARS.¹⁹⁻²¹ These pneumonic changes did not respond to antibacterial treatment.²² The patient was treated with oseltamivir for the possibility of infection with the H1N1 swine flu virus. Hematologic changes were evident in this patient in the form of lymphopenia, neutrophilia, and late thrombocytopenia. Abnormal hematologic variables were also quite common among patients with SARS. Lymphopenia was the most common finding in a cohort of 157 patients with SARS. In those patients, postmortem findings showed lymphopenia in various lymphoid organs with no features of bone marrow failure or reactive hemophagocytic syndrome.²³ The patient also had progressive impairment of renal function, similar to what had been described in some patients with SARS and possibly attributed to direct infection of renal tissue by the virus. The renal impairment in this case started on the 9th day of symptoms and progressed over the course of the patient's illness.

No symptoms were observed in the hospital among doctors and nurses caring for the patient, which suggests that the disease did not spread readily. However, staff members were not

tested for antibodies against the virus for confirmation. Now that the genome sequence of HCoV-EMC has become available and rapid diagnostic tests specific for HCoV-EMC have been developed,²⁴ thorough epidemiologic investigations are warranted. Such studies should initially focus on identifying the original source of the virus (including bats and other animal species) and potential transmission events between the infected patient and direct contacts. The development of serologic assays for surveillance studies is important.

Three months after the hospitalization of the patient in Jeddah, it was reported that a second patient with a history of travel to Saudi Arabia who had been transferred from a hospital in Qatar to a hospital in London was infected with the same virus.²⁵ At present, links between the two infected patients or a potential common source of infection have not been identified. No additional cases have been identified, although several are still under investigation. Epidemiologic investigations, active case findings with the

use of updated case definitions,²⁵ and syndrome surveillance in combination with sensitive diagnostic tests will be key to monitoring the present situation and — if necessary — to intervene in a potential outbreak. It will be equally important to test whether HCoV-EMC fulfills Koch's postulates as the causative agent of severe respiratory disease.

This case is a reminder that although most infections with human coronaviruses are mild and associated with common colds, certain animal and human coronaviruses may cause severe and sometimes fatal infections in humans. Although HCoV-EMC does not have many of the worrisome characteristics of SARS-CoV, we should take notice of the valuable lessons learned during the 2003 SARS outbreak with respect to outbreak investigations and management.

Supported in part by the European Commission Seventh Framework Program for Research and Technological Development Project EMPEIRE.

Disclosure forms provided by the authors are available with the full text of this article at NEJM.org.

We thank Dr. P.L.A. Fraaij for helpful discussions and comments.

REFERENCES

1. Virus taxonomy, classification and nomenclature of viruses: ninth report of the International Committee on Taxonomy of Viruses. San Diego, CA: Academic Press, 2012.
2. Peiris JSM, Lai ST, Poon LLM, et al. Coronavirus as a possible cause of severe acute respiratory syndrome. *Lancet* 2003; 361:1319-25.
3. Drosten C, Günther S, Preiser W, et al. Identification of a novel coronavirus in patients with severe acute respiratory syndrome. *N Engl J Med* 2003;348:1967-76.
4. Rota PA, Oberste MS, Monroe SS, et al. Characterization of a novel coronavirus associated with severe acute respiratory syndrome. *Science* 2003;300:1394-9.
5. Woo PC, Wang M, Lau SK, et al. Comparative analysis of twelve genomes of three novel group 2c and group 2d coronaviruses reveals unique group and subgroup features. *J Virol* 2007;81:1574-85.
6. van Boheemen S, Bestebroer TM, Verhagen JH, et al. A family-wide RT-PCR assay for detection of paramyxoviruses and application to a large-scale surveillance study. *PLoS One* 2012;7(4):e34961.
7. Tong S, Chern SW, Li Y, Pallansch MA, Anderson LJ. Sensitive and broadly reactive reverse transcription-PCR assays to detect novel paramyxoviruses. *J Clin Microbiol* 2008;46:2652-8.
8. Vijgen L, Moës E, Keyaerts E, Li S, Van Ranst M. A pan-coronavirus RT-PCR assay for detection of all known coronaviruses. *Methods Mol Biol* 2008;454:3-12.
9. Verstrepen WA, Kuhn S, Kockx MM, Van De Vyvere ME, Mertens AH. Rapid detection of enterovirus RNA in cerebrospinal fluid specimens with a novel single-tube real-time reverse transcription-PCR assay. *J Clin Microbiol* 2001;39:4093-6.
10. Jothikumar N, Cromeans TL, Hill VR, Lu X, Sobsey MD, Erdman DD. Quantitative real-time PCR assays for detection of human adenoviruses and identification of serotypes 40 and 41. *Appl Environ Microbiol* 2005;71:3131-6.
11. Welsh J, McClelland M. Fingerprinting genomes using PCR with arbitrary primers. *Nucleic Acids Res* 1990;18:7213-8.
12. Peiris JS, Guan Y, Yuen KY. Severe acute respiratory syndrome. *Nat Med* 2004;10: Suppl:S88-S97.
13. Hamre D, Procknow JJ. A new virus isolated from the human respiratory tract. *Proc Soc Exp Biol Med* 1966;121:190-3.
14. McIntosh K, Dees JH, Becker WB, Kapikian AZ, Chanock RM. Recovery in tracheal organ cultures of novel viruses from patients with respiratory disease. *Proc Natl Acad Sci U S A* 1967;57:933-40.
15. van der Hoek L, Pyrc K, Jebbink ME, et al. Identification of a new human coronavirus. *Nat Med* 2004;10:368-73.
16. Fouchier RA, Hartwig NG, Bestebroer TM, et al. A previously undescribed coronavirus associated with respiratory disease in humans. *Proc Natl Acad Sci U S A* 2004;101:6212-6.
17. Woo PC, Lau SK, Li KS, et al. Molecular diversity of coronaviruses in bats. *Virology* 2006;351:180-7.
18. Woo PC, Lau SK, Chu CM, et al. Characterization and complete genome sequence of a novel coronavirus, coronavirus HKU1, from patients with pneumonia. *J Virol* 2005;79:884-95.
19. Kaw GJ, Tan DY, Leo YS, Tsou IY, Wansaicheong G, Chee TS. Chest radiographic findings of a case of severe acute respiratory syndrome (SARS) in Singapore. *Singapore Med J* 2003;44:201-4.
20. Fraaij PL, Heikkinen T. Seasonal influenza: the burden of disease in children. *Vaccine* 2011;29:7524-8.
21. Davies A, Jones D, Bailey M, et al. Extracorporeal membrane oxygenation for 2009 influenza A(H1N1) acute respiratory distress syndrome. *JAMA* 2009;302:1888-95.
22. Peiris JS, Chu CM, Cheng VC, et al. Clinical progression and viral load in a community outbreak of coronavirus-associated SARS pneumonia: a prospective study. *Lancet* 2003;361:1767-72.
23. Wong RS, Wu A, To KF, et al. Haematological manifestations in patients with severe acute respiratory syndrome: retrospective analysis. *BMJ* 2003;326:1358-62.
24. Corman VM, Eckerle I, Bleicker T, et al. Detection of a novel human coronavirus by real-time reverse-transcription polymerase chain reaction. *Euro Surveill* 2012; 17:pii=20285.
25. Novel coronavirus infection — update — revised interim case definition. Geneva: World Health Organization, 2012 (http://www.who.int/csr/don/2012_09_29/en/index.html).

Copyright © 2012 Massachusetts Medical Society.