Supplementary Appendix

This appendix has been provided by the authors to give readers additional information about their work.

Supplement to: Levy J, Lifshitz T. Bilateral blurred vision in a “healthy” adult. N Engl J Med 2010;363:964.

Supplementary Figure:
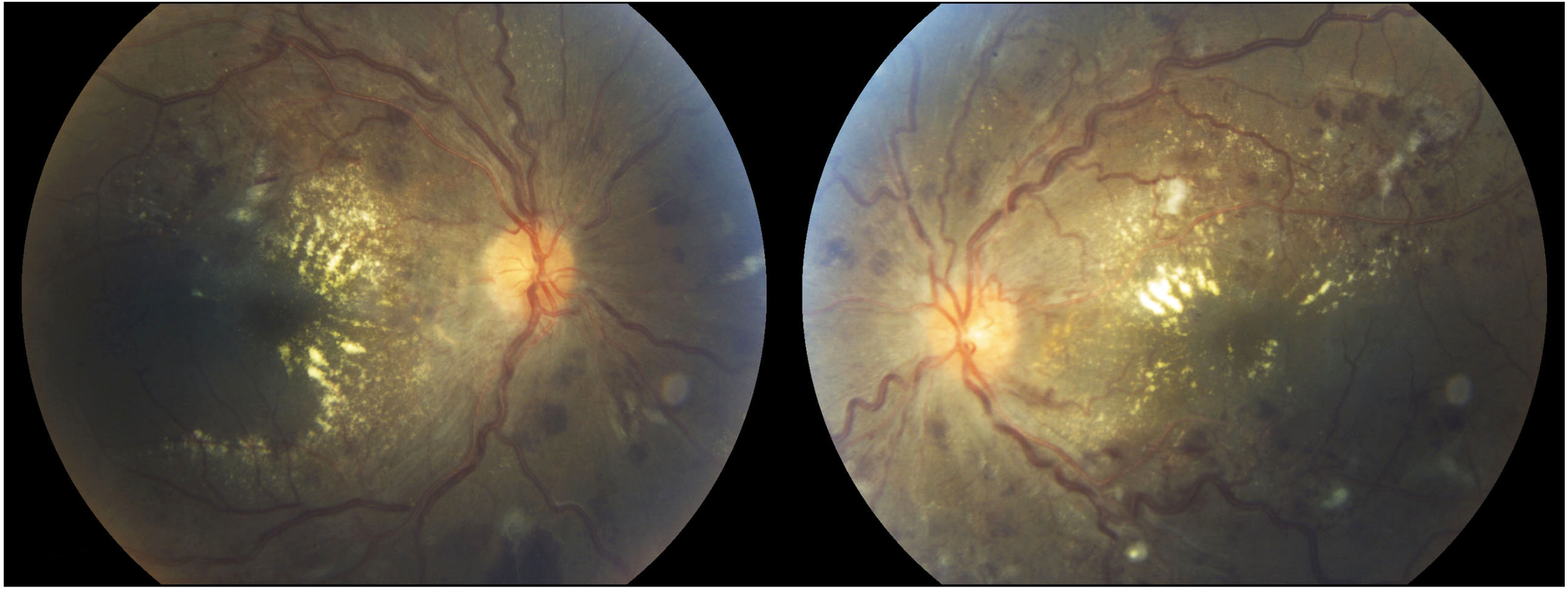
Fundus photographs 1 month after treatment for high blood pressure, showing clinical significant improvement.