

BRIEF REPORT

Visualizing Out-of-Body Experience in the Brain

Dirk De Ridder, M.D., Ph.D., Koen Van Laere, M.D., Ph.D., D.Sc.,
Patrick Dupont, Ph.D., Tomas Menovsky, M.D., Ph.D.,
and Paul Van de Heyning, M.D., Ph.D.

SUMMARY

An out-of-body experience was repeatedly elicited during stimulation of the posterior part of the superior temporal gyrus on the right side in a patient in whom electrodes had been implanted to suppress tinnitus. Positron-emission tomographic scanning showed brain activation at the temporoparietal junction — more specifically, at the angular-supramarginal gyrus junction and the superior temporal gyrus-sulcus on the right side. Activation was also noted at the right precuneus and posterior thalamus, extending into the superior vermis. We suggest that activation of these regions is the neural correlate of the disembodiment that is part of the out-of-body experience.

AN OUT-OF-BODY EXPERIENCE IS A BRIEF SUBJECTIVE EPISODE IN WHICH the self is perceived as being outside the body (disembodiment), with or without the impression of seeing the body from an elevated and distanced visuospatial perspective (autoscopy)¹ (see Glossary). Disembodiment refers to a disrupted sense of spatial unity between self and body, because the self is not experienced as residing within the limits of the body.² Thus, disembodiment refers to an abnormal self-location.

Out-of-body experiences differ from depersonalization, in which a subjective experience of unreality and detachment from the self is experienced. Depersonalization is often accompanied by derealization, in which the external world appears strange or unreal. In depersonalization and derealization, a feeling of detachment or separation from surroundings is often noted, but not a feeling of disembodiment or autoscopy.³

It has been suggested that out-of-body experiences are the result of a transient failure to integrate the visual, tactile, proprioceptive, and vestibular information that converges at the temporoparietal junction, especially on the right side of the brain.¹ Out-of-body experiences have attracted the most interest when reported by people who have had near-death experiences, but they have also been reported to occur spontaneously in patients with epilepsy or migraine¹ and have been induced by electrical stimulation of the temporoparietal junction on the right side in patients with epilepsy.^{4,5}

CASE REPORT

We report the case of a 63-year-old man in whom stimulation with implanted electrodes overlying the temporoparietal junction on the right side as a means of sup-

From the Department of Neurosurgery and Ear, Nose, and Throat, University Hospital Antwerp, Antwerp University, Antwerp, Belgium (D.D.R., T.M., P.V.H.); and the Department of Nuclear Medicine, University Hospital Leuven, Leuven, Belgium (K.V.L., P.D.). Address reprint requests to Dr. De Ridder at the Department of Neurosurgery, University Hospital Antwerp, Wilrijkstraat 10, 2650 Edegem, Belgium, or at dirk.de.ridder@neurosurgery.be.

N Engl J Med 2007;357:1829-33.

Copyright © 2007 Massachusetts Medical Society.

Glossary

- Autoscopy:** The impression of seeing one's own body from an elevated and distanced visuospatial perspective.
- Depersonalization:** The subjective experience of unreality and detachment from the self.
- Derealization:** The experience of the external world as strange or unreal.
- Disembodiment:** An experience in which the self is perceived as being outside the body.
- Out-of-body experience:** A brief subjective episode of disembodiment, with or without autoscopy.

pressing intractable tinnitus⁶ consistently induced out-of-body experiences without autoscopy. Only certain stimulation parameters induced the experiences, which lasted long enough (17 seconds on average) to allow us to conduct a placebo-controlled series of stimulations while positron-emission tomography (PET) was performed. PET data suggested that activation of a small area at the junction of the angular–supramarginal gyrus (a cortical region associated with multisensory integration¹), combined with activation of a second area in the posterior part of the superior temporal cortex (a region associated with self-perception⁷), elicited the feeling of disembodiment without autoscopy.

METHODS

The patient had tinnitus that had not responded to medical, psychological, and psychiatric treatments, including antiepileptic, antidepressant, and neuroleptic medications. A paddle electrode (Lamitrode 44, ANS Medical) was implanted, overlying the superior temporal gyrus at the junction of the angular gyrus on the right side (Fig. 1A and 1B). The surgical procedure was performed in an attempt to suppress unilateral tinnitus, as described previously.^{6,8} The procedure was approved by our institutional review board, and written informed consent was obtained from the patient.

The pitch of the patient's tinnitus was initially matched by presenting sounds in the ear contralateral to the tinnitus. Subsequently, the patient underwent functional magnetic resonance imaging (fMRI), during which the sound matched to the patient's tinnitus was presented in both ears. This evoked an area of blood-oxygenation-level-dependent (BOLD) activation in the auditory cortex that was used as a spatial target for stimulation. Electrode implantation was accomplished by coregistering the fMRI data in a neuronavigation system (Treon Stealth, Medtronic) and first using

transcranial magnetic stimulation in an attempt to suppress the tinnitus temporarily. Once placebo-controlled tinnitus suppression had been achieved, an extradural octopolar electrode was implanted in a position overlying the BOLD-activated area of the secondary auditory cortex, with the use of auditory fMRI-guided neuronavigation. Unfortunately, the electrical stimulation did not suppress the tinnitus, but out-of-body experiences were consistently induced and are the subject of this report.

Twelve PET scans of the brain with the use of oxygen-15–labeled water were obtained during three different conditions of 70-second stimulation trains, beginning 10 seconds before the start of the 1-minute scan: 3.7 V at 40-Hz tonic mode (condition 1 [C1]), 2.7 V at 40-Hz burst mode (condition 2 [C2]), and 3.7 V at 40-Hz burst mode (condition 3 [C3]). Conditions 1 and 2 were replicated three times each and condition 3 was replicated six times, in a randomized design with the following sequence of conditions: 132332311323. The patient indicated the start and end of an out-of-body experience by pressing a button with his right hand, and his subjective reporting was registered immediately after each scan.

RESULTS

Stimulation at 3.7 V in 40-Hz burst mode (5 spikes at 500 Hz), with a 1-msec pulse width and a 1-msec interval between spikes, repeated 40 times per second (C3) reproduced, in a controlled way, a state of disembodiment without an alteration in the patient's level of consciousness. The patient had the experience within 1 second after the initiation of stimulation. His perception of disembodiment always involved a location about 50 cm behind his body and off to the left. There was no autoscopy and no voluntary control of movements of the disembodied perception. The environment was visually perceived from his real-person perspective, not from the disembodied perspective. Stimulation at these specific settings had similar effects whether the patient was in a sitting or lying position. During the initial stimulations, when he was sitting, the patient could see the stimulation room. During the imaging experiments, however, he was lying supine in a dimly lit room. As stated above, his out-of-body experience lasted for 17 seconds on average (range, 15 to 21). Stimulation at 3.7 V at 40 Hz in tonic mode (single-pulse stimulation at 40 Hz) (C1) did not induce an out-of-body experience, nor did stim-

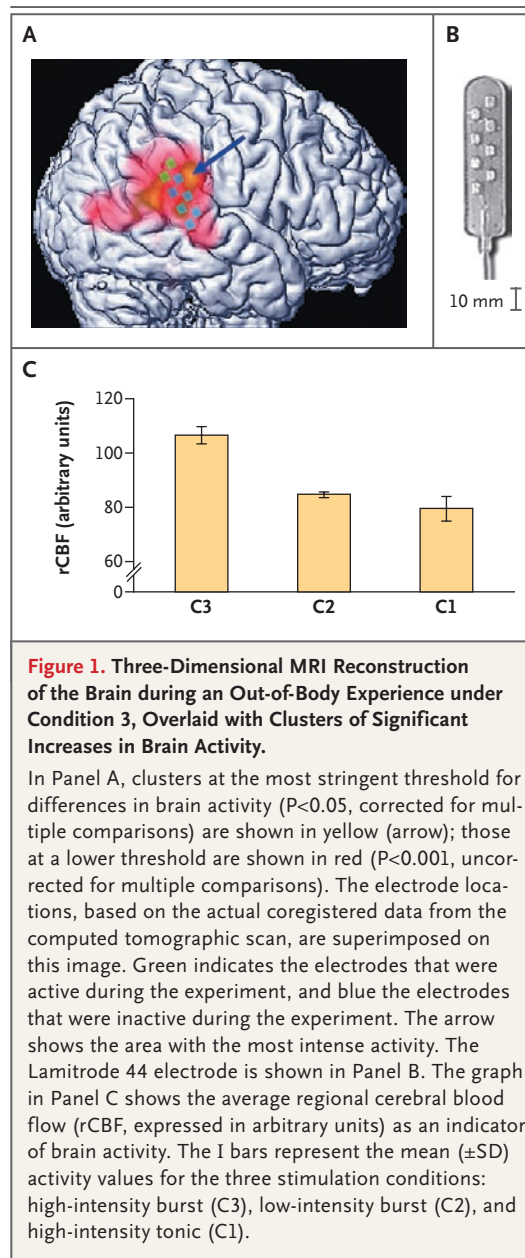
ulation at a lower voltage (2.7 V) at 40-Hz burst mode (C2).

Statistical parametric mapping of the PET data showed highly significant increased activity in a cluster at the temporoparietal junction on the right side (Fig. 1A and 1C), with local maxima just at the angular-supramarginal gyrus junction (Montreal Neurological Institute [MNI] peak coordinates $x, y, z = 58, -46, 10$; T statistic = 16.8; voxel intensity difference $P_{\text{height}} = 0.005$, corrected for multiple comparisons [$P_{\text{height}} = P$ value for the difference in intensity — the voxel value at the peak coordinate given]; cluster extent = 124 voxels of $2 \times 2 \times 2 \text{ mm}^3$; $P < 0.001$) and at the posterior part of the superior temporal sulcus-gyrus (MNI peak coordinates $x, y, z = 58, -32, 6$; T statistic = 13.3; voxel intensity difference $P_{\text{height}} = 0.04$, corrected for multiple comparisons; cluster extent = 163 voxels; $P < 0.001$). At the lower confidence level of voxel values, with $P_{\text{height}} < 0.001$ (uncorrected for multiple comparisons), two additional clusters of activation were detected: one in the right precuneus on the right side and one in a region extending from the posterior thalamus to the cerebellar upper vermis (Fig. 2).

DISCUSSION

It has been suggested that an out-of-body experience results from a deficient multisensory integration at the temporoparietal junction on the right side.¹ This hypothesis has been developed from data on lesions, the results of transcranial magnetic stimulation, and electrophysiological findings in healthy volunteers and patients with epilepsy,⁹ as well as from single-scan, ictal single-photon-emission computed tomographic imaging and interictal PET imaging in patients with epilepsy.¹ We used functional neuroimaging with a controlled design to capture the regions of the brain that are engaged during an isolated, pure state of disembodiment. The consistency of the evoked out-of-body experience in our patient and its relatively long duration allowed for the use of PET scanning to visualize brain areas that were activated during the out-of-body experience.

The activation of the area at the junction of the angular gyrus and the supramarginal gyrus on the right side is probably related to the feeling of disembodiment and may be a consequence of disrupted somatosensory (mainly proprioceptive) and vestibular integration. The supramarginal gyrus on the right side of the brain in humans is in-



involved in the processing of vestibular information for head and body orientation in space.¹⁰ Electrical stimulation of the angular gyrus on the right side induces vestibular and complex somatosensory responses,⁵ suggesting that the angular-supramarginal junction might be involved in the vestibular somatosensory integration of body orientation in space.

The general area of the superior temporal cortex has been thought to embody an internal map of self-perception, as one component of human self-consciousness.⁷ During disembodiment, self-

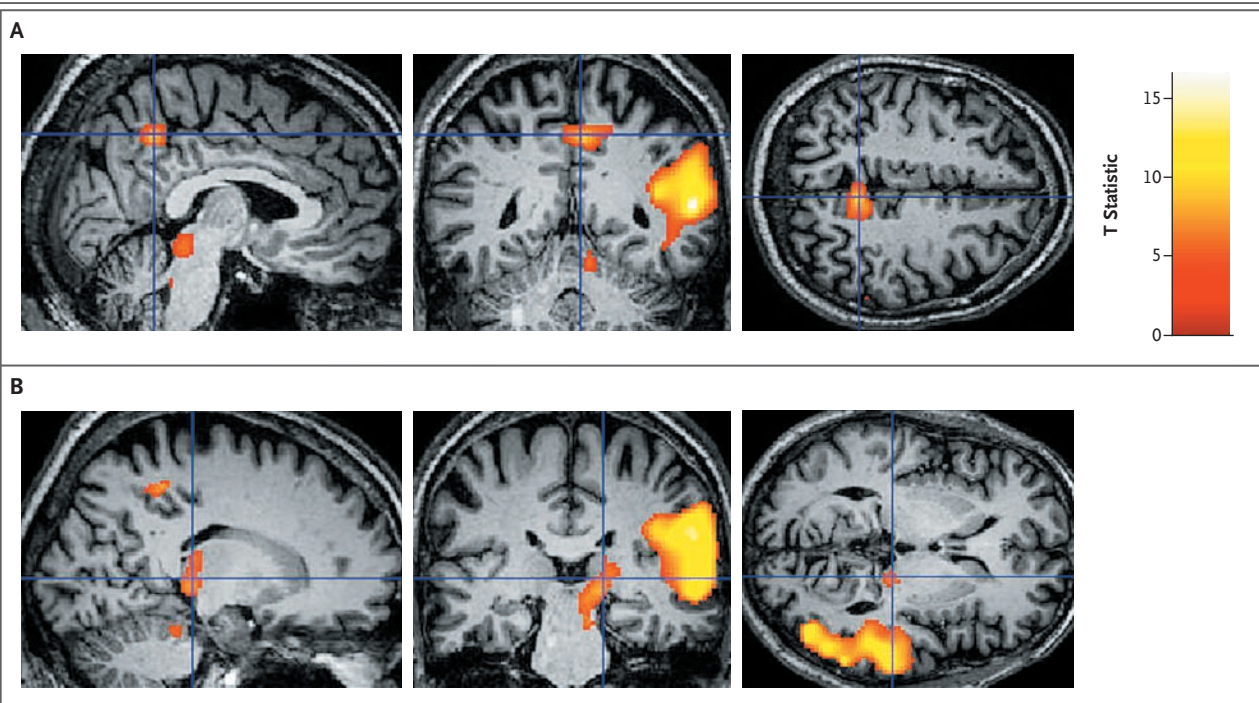


Figure 2. Additional Clusters of Activity in the Patient's Brain during an Out-of-Body Experience.

Panel A shows the additional cluster of activity in the precuneus on the right side of the brain during an out-of-body experience, with the blue cross indicating the voxel with the maximal difference in activity. Panel B shows the additional cluster of activity in the posterior thalamus, extending to the upper cerebellar vermis, with the blue cross indicating the voxel with the maximal difference in activity. $P < 0.001$ (uncorrected for multiple comparisons) for all images. The color scale represents the T statistic for each voxel in the cluster.

perception is altered, but global self-consciousness is retained. In contrast, during depersonalization and derealization, both global self-consciousness and self-perception are retained, but the person feels dissociated from the surroundings.³ Imaging studies have revealed that dissociation and depersonalization scores in subjects with depersonalization disorder are significantly related to metabolic activity in the inferior parietal cortex (Brodmann's area 7B), suggesting that spatial mislocalization of the self in relation to the physical body (disembodiment) is associated with activation of the angular-supramarginal junction, as we have shown, whereas spatial mislocalization of the self in the surrounding environment may be associated with somewhat more dorsally located inferior parietal activation.¹¹

In addition, the precuneus has been implicated as part of a functional network generating reflective self-awareness as a core function of consciousness.¹² PET imaging has shown that the angular gyrus, anterior cingulate gyrus, and precuneus are functionally connected and synchronously active

during reflective self-awareness.¹² The precuneus is reciprocally connected to both the posterior thalamus complex and the inferior parietal lobule-temporoparietal junction.¹³

Two patients have been described in whom out-of-body experiences were evoked by electrical stimulation of the right temporoparietal junction. The patient described by Penfield had a floating feeling without autoscopia, induced by electrical stimulation of the posterior part of the superior temporal gyrus, anterior to the angular gyrus.⁴ In the patient described by Blanke et al., who had autoscopia, the stimulation target was more posterior, at the occipital side of the angular gyrus,⁵ potentially explaining the associated autoscopia, which was absent in our patient and in the patient described by Penfield. Thus, autoscopia could be the result of coactivation of more posteriorly located visual pathways, whereas disembodiment could be the result of predominantly somatosensory-vestibular disintegration at the junction of the supramarginal gyrus and the angular gyrus.

Conclusions regarding the anatomical origins

of spontaneous and electrically elicited out-of-body experiences in patients with epilepsy have been questioned because cortical reorganization is known to take place in some of these patients. It has also been suggested that both tinnitus and epilepsy are the result of dysrhythmic thalamocortical oscillations.¹⁴ A subgroup of people with epilepsy undergo progressive brain atrophy accompanied by functional decline, both of which worsen with the duration of epilepsy.¹⁵ For these reasons, it is not clear whether out-of-body experiences might be a normal consequence of coactivation of two areas that do not usually function together or whether they arise only in the presence of pathological brain states such as epilepsy or tinnitus. Studies of depersonalization and derealization have demonstrated that caloric stimulation can induce a feeling of detachment or separation from surroundings both in healthy subjects and in patients with vestibular disorders.³ However, the symptoms occur spontaneously only in patients with vestibular disorders.³ It could be hypothe-

sized that a similar mechanism is at work in out-of-body experiences — that is, they may occur spontaneously only in pathologic brains but can be induced in nonpathologic brains.

Our PET data suggest that the experience of disembodiment is mediated by coactivation of a small area at the junction of the angular and supramarginal gyrus and the superior temporal gyrus–sulcus. Activation of the angular and supramarginal gyrus junction alters vestibular–somatosensory integration of body orientation in space. Coactivation of the posterior part of the superior temporal cortex, with its internal map of self-perception, results in altered spatial self-perception. Whether these regions are activated in patients who report disembodiment as part of a near-death experience — and if so, how — is a provocative but unresolved issue.

No potential conflict of interest relevant to this article was reported.

We thank Jay Gunkelman for reviewing an earlier version of the manuscript, and Tim Vancamp for his support.

REFERENCES

1. Blanke O, Mohr C. Out-of-body experience, heautoscopy, and autoscopic hallucination of neurological origin: implications for neurocognitive mechanisms of corporeal awareness and self-consciousness. *Brain Res Brain Res Rev* 2005;50:184-99.
2. Blanke O, Landis T, Spinelli L, Seeck M. Out-of-body experience and autoscopia of neurological origin. *Brain* 2004;127:243-58. [Erratum, *Brain* 2004;127:719.]
3. Sang FY, Jáuregui-Renaud K, Green DA, Bronstein AM, Gresty MA. Depersonalisation/derealisation symptoms in vestibular disease. *J Neurol Neurosurg Psychiatry* 2006;77:760-6.
4. Tong F. Out-of-body experiences: from Penfield to present. *Trends Cogn Sci* 2003;7:104-6.
5. Blanke O, Ortigue S, Landis T, Seeck M. Stimulating illusory own-body perceptions. *Nature* 2002;419:269-70.
6. De Ridder D, De Mulder G, Verstraeten E, et al. Primary and secondary auditory cortex stimulation for intractable tinnitus. *ORL J Otorhinolaryngol Relat Spec* 2006;68:48-54.
7. Vogeley K, May M, Ritzl A, Falkai P, Zilles K, Fink GR. Neural correlates of first-person perspective as one constituent of human self-consciousness. *J Cogn Neurosci* 2004;16:817-27.
8. De Ridder D, De Mulder G, Walsh V, Muggleton N, Sunaert S, Möller A. Magnetic and electrical stimulation of the auditory cortex for intractable tinnitus: case report. *J Neurosurg* 2004;100:560-4.
9. Blanke O, Mohr C, Michel CM, et al. Linking out-of-body experience and self processing to mental own-body imagery at the temporoparietal junction. *J Neurosci* 2005;25:550-7.
10. Stephan T, Deuschländer A, Nolte A, et al. Functional MRI of galvanic vestibular stimulation with alternating currents at different frequencies. *Neuroimage* 2005;26:721-32.
11. Simeon D, Guralnik O, Hazlett EA, Spiegel-Cohen J, Hollander E, Buchsbaum MS. Feeling unreal: a PET study of depersonalization disorder. *Am J Psychiatry* 2000;157:1782-8.
12. Kjaer TW, Nowak M, Lou HC. Reflective self-awareness and conscious states: PET evidence for a common midline parietofrontal core. *Neuroimage* 2002;17:1080-6.
13. Cavanna AE, Trimble MR. The precuneus: a review of its functional anatomy and behavioural correlates. *Brain* 2006;129:564-83.
14. Llinás RR, Ribary U, Jeanmonod D, Kronberg E, Mitra PP. Thalamocortical dysrhythmia: a neurological and neuropsychiatric syndrome characterized by magnetoencephalography. *Proc Natl Acad Sci U S A* 1999;96:15222-7.
15. Sutula TP. Mechanisms of epilepsy progression: current theories and perspectives from neuroplasticity in adulthood and development. *Epilepsy Res* 2004;60:161-71.

Copyright © 2007 Massachusetts Medical Society.