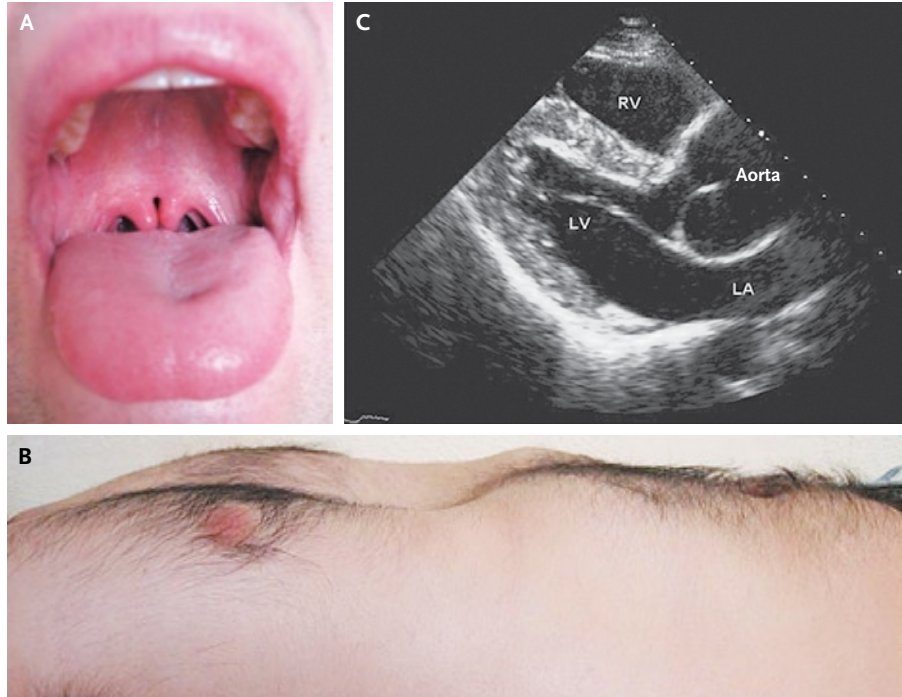


## IMAGES IN CLINICAL MEDICINE

## Bifid Uvula and Aortic Aneurysm



Isidre Vilacosta, M.D.  
 Victoria Cañadas Godoy, M.D.  
 Hospital Clinico San Carlos  
 E-28040 Madrid, Spain

A 24-YEAR-OLD MAN WAS HOSPITALIZED FOR EVALUATION OF AN AORTIC-root aneurysm. He had a family history of aortic disease. Physical examination revealed proptosis, retrognathia, bifid uvula (Panel A), and pectus excavatum (Panel B). Transthoracic echocardiography showed a 50 mm by 50 mm aortic-root aneurysm (Panel C; RV denotes right ventricle, LV left ventricle, and LA left atrium). The presence of the classic triad of craniofacial abnormalities, aortic aneurysm, and bifid uvula, as well as the family history of aortic disease, strongly suggested a diagnosis of Loeys–Dietz syndrome type 1, which was confirmed by genetic analysis showing a mutation in exon 7 of the *TGFBR2* gene. Patients with this autosomal dominant syndrome are at high risk for aortic dissection or rupture at an early age; the aortic diameter may not be predictive of rupture. The patient underwent successful aortic-root replacement and remains well at 1 year of follow-up.

Copyright © 2008 Massachusetts Medical Society.