

CLINICAL THERAPEUTICS

Artesunate for the Treatment of Severe *Falciparum* Malaria

Philip J. Rosenthal, M.D.

This Journal feature begins with a case vignette that includes a therapeutic recommendation. A discussion of the clinical problem and the mechanism of benefit of this form of therapy follows. Major clinical studies, the clinical use of this therapy, and potential adverse effects are reviewed. Relevant formal guidelines, if they exist, are presented. The article ends with the author's clinical recommendations.

A previously well, American-born 35-year-old man presents with a 5-day history of fever and progressive dyspnea and a 2-day history of jaundice. An evaluation 3 days before his presentation led to a diagnosis of a viral syndrome. The patient had returned 3 weeks earlier from a 1-month stay in West Africa. He reports receiving immunizations before travel and taking pills to prevent malaria weekly until his return to the United States.

The physical examination shows moderate respiratory distress, diffuse pulmonary crackles, and mild jaundice. His vital signs include a temperature of 39.8°C, respiratory rate of 32 breaths per minute, and oxygen saturation of 87% while he is breathing ambient air. Abnormal results of laboratory tests include a hematocrit of 32.2%, platelet count of 78 per cubic millimeter, total bilirubin level of 4.2 mg per deciliter (71.8 μmol per liter), and creatinine level of 2.2 mg per deciliter (194.5 μmol per liter). A Giemsa-stained blood smear shows numerous ring forms of *Plasmodium falciparum*, with parasitemia estimated at 2%. He is immediately hospitalized, and an infectious-disease consultant recommends that the Centers for Disease Control and Prevention (CDC) be contacted to obtain intravenous artesunate for his treatment.

THE CLINICAL PROBLEM

Malaria is one of the most important infectious diseases in the world, causing hundreds of millions of illnesses and an estimated 1 million deaths each year.¹ Malaria is endemic throughout most of the tropics, but it is most readily transmitted in sub-Saharan Africa. Nearly all serious illnesses and deaths from malaria are caused by *P. falciparum*.

Severe malaria, which is much less common than uncomplicated disease, is difficult to define precisely, especially in regions where malaria is endemic, because other serious illnesses can coexist with malarial infection. Severe malaria is generally defined as acute malaria with major signs of organ dysfunction or high levels of parasitemia (Table 1).² In areas where malaria is endemic, young children are at high risk for severe malaria. Partial immunity develops in older children and adults after repeated infections, and they are thus at relatively low risk for severe disease. Pregnant women are also at increased risk for severe malaria.⁴

Travelers to areas where malaria is endemic often contract the disease, mostly because of lack of compliance with preventive measures such as the avoidance of night-biting anopheline mosquitoes and use of chemoprophylaxis. Travelers generally have no previous exposure to malaria parasites and so are at high risk for pro-

From the Department of Medicine, San Francisco General Hospital, University of California, San Francisco. Address reprint requests to Dr. Rosenthal at Box 0811, University of California, San Francisco, San Francisco, CA 94143, or at prosenthal@medsfgh.ucsf.edu.

N Engl J Med 2008;358:1829-36.
Copyright © 2008 Massachusetts Medical Society.

Table 1. Characteristics of Severe Malaria.*

Clinical Manifestations	Features Associated with a Poor Prognosis
Physical findings	
Prostration	
Impaired consciousness	Coma
Respiratory distress, pulmonary edema	Tachypnea, labored deep breathing
Repeated seizures	≥3 seizures in 24 hr
Shock	Systolic blood pressure <80 mm Hg after volume repletion
Abnormal bleeding	Retinal hemorrhages
Jaundice	
Acute renal failure	Fluid and electrolyte abnormalities
Macroscopic hemoglobinuria	
Abnormal results of laboratory tests	
Severe anemia	Hematocrit <15% or hemoglobin <0.5 g/dl
Hypoglycemia	Blood glucose <2.2 mmol/liter
Metabolic acidosis	Plasma bicarbonate <15 mmol/liter or blood pH <7.25
Renal insufficiency	Serum creatinine >250 μmol/liter
Hyperlactatemia	Venous lactate >4 mmol/liter
Hyperparasitemia	>500,000 parasites/mm ³ or >5–10% parasitemia
Elevated aminotransferase levels	Aminotransferase levels >3 times the upper limit of the normal range
Elevated bilirubin level	Serum bilirubin >50 μmol/liter
Disseminated intravascular coagulation	

* Data are adapted from the World Health Organization² and Hoffman et al.³ To convert the values for hemoglobin to millimoles per liter, multiply by 0.6206. To convert the values for glucose to milligrams per deciliter, divide by 0.05551. To convert the values for creatinine to milligrams per deciliter, divide by 88.4. To convert the values for lactate to milligrams per deciliter, divide by 0.1110. To convert the values for bilirubin to milligrams per deciliter, divide by 17.1.

gression to severe disease if they are infected with *P. falciparum*.⁵ In a large survey of travel clinics, malaria was the most frequent cause of fever without localizing findings, and it was particularly common in febrile travelers returning from Africa.⁶ In recent years, approximately 1000 to 1600 episodes of malaria have been diagnosed each year in Americans after return from travel⁷; approximately 5 to 10% of these cases are estimated to meet criteria for severe malaria.⁸ Thus, although it is important to consider malaria in all febrile patients with a history of travel to areas where malaria is endemic, American physicians frequently do not do so. During the period from 1985 to 2001, the case fatality rate for *P. falciparum* infections in the United States was estimated at 1.3%, and delayed diagnosis contributed to poor outcomes in many cases.⁹

PATHOPHYSIOLOGY AND EFFECT OF THERAPY

When an infectious anopheline mosquito bites, it injects sporozoites, which circulate and invade hepatocytes (Fig. 1). After asymptomatic hepatic infection (lasting 1 to 2 weeks in the case of *P. falciparum* infection), merozoites are released and invade erythrocytes. The asexual erythrocytic stage of infection is responsible for all clinical aspects of malaria. In erythrocytes, parasites develop into ring forms, mature trophozoites, and then multinucleated schizonts, which rupture and release more merozoites. Repeated cycles of erythrocyte invasion and rupture lead to chills, fever, headache, fatigue, other nonspecific symptoms, and, with severe malaria, signs of organ dysfunction (Table 1). Some parasites develop into gametocytes, which may be taken up by mosquitoes, in which sexual reproduction and further development of the parasites lead to the generation of a new set of infectious sporozoites.

A key feature of the life cycle of *P. falciparum* is cytoadherence, whereby erythrocytes infected with mature parasites adhere to endothelial cells in the microvasculature.¹⁰ This process is presumably advantageous to the parasite, since it prevents the passage of abnormal erythrocytes through the spleen. High concentrations of *P. falciparum*-infected erythrocytes in the microvasculature and a complex interplay of host and parasite factors lead to the manifestations of severe malaria, including cerebral malaria, noncardiogenic pulmonary edema, and renal failure.¹¹ Because of the ability of mature *P. falciparum* organisms in the erythrocytic stage to adhere to endothelial cells, only ring forms circulate (except in very severe infections), and levels of peripheral parasitemia may be quite low despite substantial infection.

Many drugs are available for the treatment of uncomplicated malaria (i.e., malaria that is not classified as severe).^{12,13} However, control in areas where malaria is endemic is limited by drug resistance, the toxic effects of some agents, and the relatively high cost and limited availability of newer drugs. Intravenous quinine and — in the United States — intravenous quinidine have been the standard therapies for severe cases of falciparum malaria for many years.

The most important new class of antimalarial agents is the artemisinins, which are natural products developed in China beginning in the 1960s.¹⁴

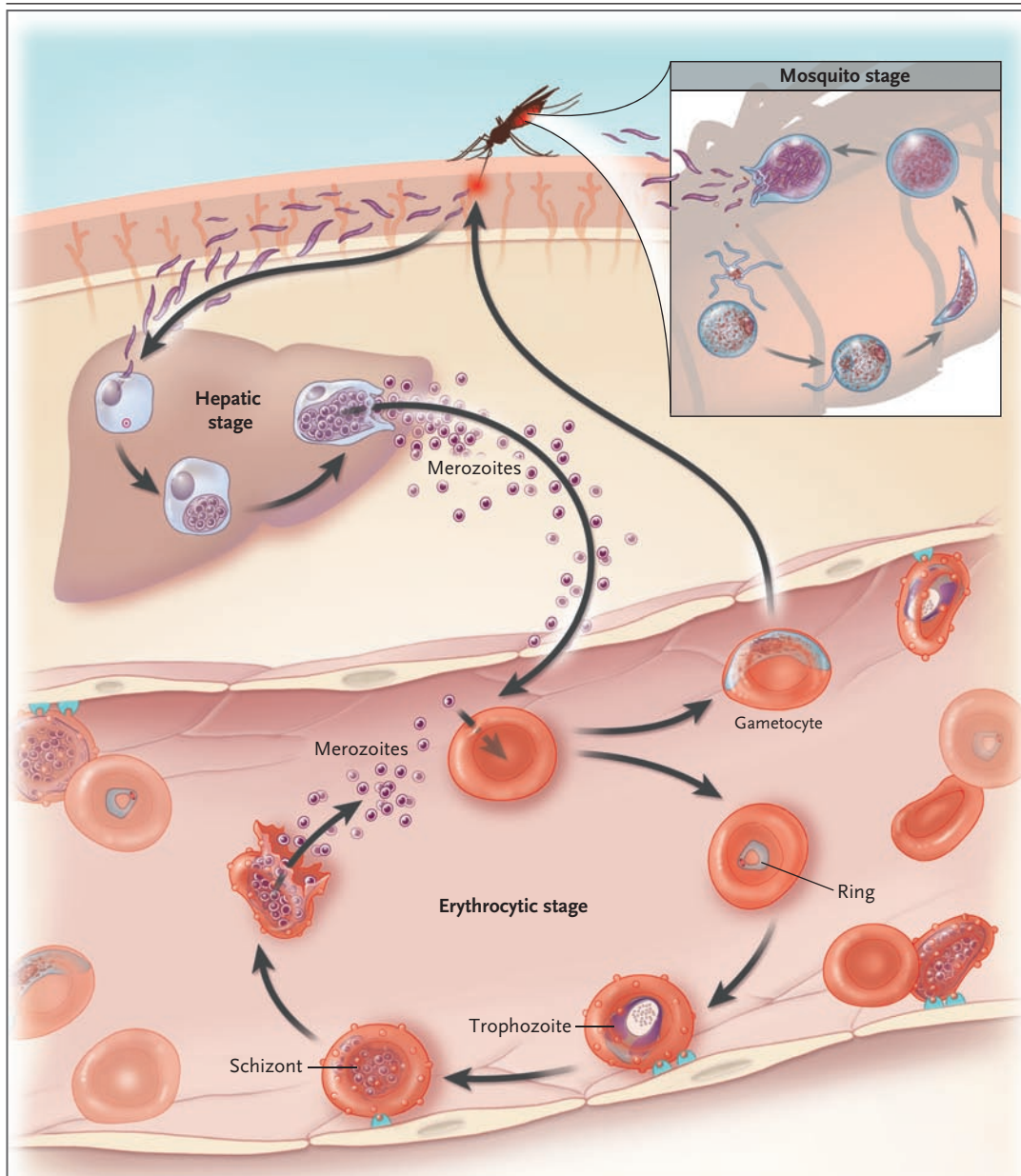


Figure 1. Life Cycle of *Plasmodium falciparum*.

Elements that are important for the pathogenesis of severe malaria are shown. Erythrocytes containing *P. falciparum* in mature intraerythrocytic stages (trophozoites and schizonts) adhere to vascular endothelium, thereby avoiding clearance by the spleen. High numbers of circulating parasites and elaboration of host and parasite factors in the vasculature of various organs lead to the manifestations of severe malaria.

A number of artemisinin derivatives in addition to the parent compound are now available, including artesunate, artemether, artemotil, and dihydroartemisinin. Although the mechanisms of action of artemisinins are not fully understood, they may include free-radical production in the para-

site food vacuole¹⁵ and inhibition of a parasite calcium ATPase.¹⁶ A key advantage of artemisinins is rapid action against all of the erythrocytic stages of the parasite, including transmissible gametocytes, resulting in a rapid clinical benefit and decreased transmission of malaria (Fig. 1).

In addition, there is currently limited, if any, resistance to artemisinins in malaria parasites. Although all artemisinins have rapid antiparasitic activity, they have short half-lives, such that the standard 3-day treatment course is commonly followed by recrudescence of infecting parasites and recurrent illness within days to weeks.¹⁴ To help prevent late recrudescences and the emergence of resistant parasites, these drugs should always be used in combination with a longer-acting agent. Fixed-dose combinations for oral therapy of uncomplicated malaria, known as artemisinin-based combination therapy, have been developed recently.

CLINICAL EVIDENCE

When used correctly, chemoprophylaxis appears to be highly effective in preventing malaria.⁵ The drugs recommended by the CDC to prevent malaria in travelers to areas with drug-resistant falciparum malaria (i.e., most regions of the world where malaria is endemic) are mefloquine, atovaquone–proguanil, and doxycycline.⁵ In the vignette, the patient's weekly regimen was presumably mefloquine, but he apparently did not continue to receive the drug for 4 weeks after travel, as is required to eradicate parasites that emerge from the liver some weeks after exposure.

Treatment of malaria is generally highly effective when provided rapidly, used correctly, and not limited by drug resistance.¹² Approved therapies for treatment of uncomplicated falciparum malaria in the United States include atovaquone–proguanil, quinine (a 3-day course plus a 1-week course of doxycycline or, in children, clindamycin), and mefloquine.¹⁷ For severe malaria, which is best treated intravenously, the only therapy available in the United States in recent years has been intravenous quinidine, which is generally highly efficacious. However, quinine and quinidine are associated with considerable toxic effects, including tinnitus, reversible hearing loss, nausea, vomiting, dizziness, hypoglycemia, and visual disturbances. As compared with quinine, intravenous quinidine is associated with greater risks of cardiotoxic effects and hypotension.¹⁸ The antimalarial efficacy of quinine has diminished in some areas, in particular Southeast Asia,¹⁹ suggesting partial resistance that may limit the drug's efficacy against severe malaria.

Artemisinin-based combination therapies, in-

cluding artesunate–mefloquine, artemether–lumefantrine, artesunate–amodiaquine, and dihydroartemisinin–piperaquine, are highly efficacious,^{20–25} and they are now listed as first-line therapies for uncomplicated malaria in most countries where malaria is endemic. No artemisinin-based combination therapies are yet available in the United States. The rapid reduction in the level of parasitemia with the use of artemisinins has also led to interest in their use for the treatment of severe malaria. Intravenous and intramuscular artemisinins have been highly efficacious for the treatment of severe malaria (see below). Rectal administration is also effective and may be of value in settings with limited resources.²⁶

The first artemisinin to be studied in large clinical trials of severe malaria was artemether. Large randomized comparisons of intramuscular artemether and quinine in Gambian children²⁷ and Vietnamese adults²⁸ and a meta-analysis of individual data from 1919 patients in 11 trials of parenteral therapy²⁹ identified no significant difference in efficacy between these agents. However, in the meta-analysis, the subgroup of adults had lower mortality when treated with artemether.

The efficacy of intramuscular artemether in severe malaria may be limited by varied absorption of this fat-soluble artemisinin derivative. Artesunate, which is water-soluble, has more reliable pharmacokinetic characteristics.³⁰ A large, randomized comparison of intravenous artesunate and quinine in 1461 patients in Asia showed a significant survival benefit with artesunate. Mortality was 22% with quinine, as compared with 15% with artesunate, a risk reduction of 34.7%.³¹ Treatment with artesunate had a relatively mild side-effect profile; hypoglycemia was significantly more common with the use of quinine. A systematic review of five randomized trials comparing the efficacy of intravenous quinine with that of artesunate and one additional trial of intramuscular artesunate demonstrated the superiority of artesunate, with significant reductions in the risk of death (relative risk, 0.62), incidence of hypoglycemia, and parasite clearance time, as compared with quinine.³²

CLINICAL USE

Of primary importance in the treatment of severe malaria are the provision of prompt, effective therapy and concurrent supportive care to man-

age life-threatening complications of the disease.² In most of the world, standard therapy has been intravenous or intramuscular quinine. In the United States, intravenous quinidine has been the standard therapy since 1991. That year, parenteral quinine was withdrawn by the CDC because quinidine had been shown to be more potent in vitro and highly effective against *P. falciparum* when used orally for uncomplicated disease³³ or intravenously for severe falciparum malaria.³⁴ The current recommendations for severe malaria are to administer quinidine as a loading dose followed by continuous infusion; the loading dose may be omitted if quinine or mefloquine was recently administered.^{2,17} The cardiac toxic effects of quinidine are a major concern, and intravenous therapy requires continuous cardiac monitoring, with slowing or discontinuation of the infusion for prolongation of the QT interval. Another problem has been the decreasing availability of quinidine as the use of the drug as an antiarrhythmic agent has decreased.³⁵

With emerging evidence of the superiority of artesunate over quinine or quinidine, an investigational-new-drug (IND) application from the CDC went into effect in the United States on June 21, 2007, to allow investigational use of intravenous artesunate for the treatment of severe malaria. The drug is not approved by the Food and Drug Administration, and it can be used in the United States only through the IND application, with the drug supplied at no charge by the Walter Reed Army Institute of Research. Patients are eligible if they have uncomplicated malaria but require parenteral therapy because of an inability to take oral medications or if they have a level of parasitemia of more than 5% or other signs of severe malaria (Table 1). In addition, the CDC requires that artesunate be at least as rapidly available for administration as quinidine or that there be known intolerance of quinidine, previous failure of such treatment, or a contraindication. Enrollment requires a telephone call to the CDC Malaria Hotline (Monday through Friday from 8 a.m. to 4:30 p.m. Eastern time, at 770-488-7788; at other times, health care providers may call 770-488-7100 and ask for a clinician in the CDC Malaria Branch). If approved, the drug will be released by the CDC Drug Service or by one of the 20 CDC quarantine stations located around the country.

Under the IND protocol, intravenous artesunate is administered in four equal doses of 2.4 mg

per kilogram of body weight over a period of 3 days. The dosing schedule recommended by the World Health Organization (WHO) entails doses every 12 hours on day 1 and then once daily. Therapy for more than 3 days may occasionally be indicated in very ill patients, but specific guidelines on when to extend therapy are not available. Artesunate dosages need not be changed because of hepatic or renal failure or concomitant or previous therapy with other medications, including previous therapy with mefloquine, quinine, or quinidine. There are no known interactions between artesunate and other drugs.

Cardiac monitoring is not mandatory during treatment with artesunate, and no serious toxic effects due to the drug are anticipated. However, patients with severe malaria often require care in an intensive care unit. Indeed, aggressive supportive care, including mechanical ventilation and hemofiltration or hemodialysis, can be instrumental in successful management of severe malaria.^{36,37} In technologically limited settings, high-quality nursing care, management of fluid balance, and control of seizures are helpful, although anticonvulsant agents that are respiratory depressants should be used with caution if mechanical ventilation is unavailable.³⁸ Aggressive fluid resuscitation, blood transfusion for moderate anemia, exchange transfusion, and specific treatment for acidosis are of uncertain value. Bacterial infections can coexist with severe malaria, so blood cultures should be obtained from patients with shock or other signs of sepsis despite appropriate antimalarial therapy, and these patients should receive broad-spectrum antibiotic therapy. Hypoglycemia will be less common when artesunate is used rather than quinine or quinidine; nonetheless, it is important to monitor the patient's blood glucose level and provide supplementary glucose as needed.

After the acute stage of the illness, artemisinins should be partnered with longer-acting drugs to ensure a high likelihood of cure. Appropriate partner drugs that are available in the United States are a 1-week course of doxycycline or, in children or pregnant women, clindamycin, or full courses of treatment with atovaquone-proguanil or mefloquine (although the neuro-psychiatric toxic effects of mefloquine may be increased after cerebral malaria). All of these drugs should be initiated after the patient can tolerate oral medication.

ADVERSE EFFECTS

Toxic effects have been reported less frequently with the artemisinins than with other antimalarial agents.³⁹ The most common toxic effects that have been identified are nausea, vomiting, anorexia, and dizziness; these are probably due, in many patients, to acute malaria rather than to the drugs.⁴⁰ More serious toxic effects, including neutropenia, anemia, hemolysis, and elevated levels of liver enzymes, have been noted rarely.⁴¹ Two cases of severe allergic reactions to oral artesunate have been reported, with an estimated risk of approximately 1 reaction per 3000 treatments.⁴²

Neurotoxicity is the greatest concern regarding artemisinins, since the administration of high doses in laboratory animals has led to severe and irreversible changes in the brain.⁴³ Extensive studies in many species showed that intramuscular dosing was more toxic than oral dosing and that, by any route, fat-soluble artemisinins were more toxic than artesunate.⁴⁴ In humans, an episode of ataxia was reported after treatment with oral artesunate,⁴⁵ and one case-control study showed hearing loss after the use of artemether-lumefantrine,⁴⁶ but auditory toxic effects were not detected in another case-control study,⁴⁷ and reported toxic effects may have been due to underlying malaria or other factors that were independent of artemisinin use. Multiple studies have shown that neurologic findings are fairly common with acute malaria, but there is no convincing evidence of neurotoxic effects resulting from standard oral or intravenous therapy with artemisinins.^{41,48,49}

Another concern about artemisinins is embryotoxic effects, which have been demonstrated in animals.⁵⁰ Studies from Asia⁵¹ and Africa,⁵² including 44 treatments during the first trimester,⁵¹ showed similar levels of congenital abnormalities, stillbirths, and abortions in patients who received and those who did not receive artesunate during pregnancy. Limited data are available on the use of intravenous artesunate for severe malaria during pregnancy.³¹

AREAS OF UNCERTAINTY

A major concern with all antimalarial drugs is resistance. The short half-lives of artemisinins limit the possibility of selection for resistance. Nonetheless, recent heavy use of artemisinins,

including monotherapy, has created selective pressure. Some parasites isolated from French Guiana and Senegal recently showed diminished *in vitro* sensitivity to artemether,⁵³ and the efficacies of artemisinin-based combination agents have apparently decreased along the Thailand-Cambodia border.⁵⁴ However, at present, the likelihood of true artemisinin resistance in malaria parasites is low, and this concern should not prevent the use of intravenous artesunate to treat severe malaria.

GUIDELINES

The WHO recommends intravenous artesunate as the treatment of choice for severe malaria in adults and children in areas of low transmission.¹³ Data on children in high-transmission regions are limited, and the WHO recommends treatment with artesunate, artemether, or quinine. For severe malaria during pregnancy, additional data regarding the risks of artemisinins are needed.⁵⁵ The WHO recommends artesunate or quinine during the first trimester and artesunate as the first-line therapy during the second and third trimesters.

RECOMMENDATIONS

The patient in the vignette meets criteria for severe falciparum malaria (Table 1) and should receive emergency treatment in an intensive care unit, with careful attention to potential serious complications, since he is at high risk for rapid clinical deterioration. In particular, his respiratory findings and altered renal status require close observation, and mechanical ventilation and hemodialysis or hemofiltration may be required as his illness progresses. Until 2007, appropriate therapy would have been intravenous quinidine. Intravenous artesunate is now available. Since it has been shown to have superior efficacy and is likely to have fewer side effects and a better safety profile than intravenous quinidine, it is now appropriate therapy as long as it can be acquired promptly. This last point is a major concern, since intravenous artesunate will only be available rapidly for hospitals near CDC quarantine stations. If artesunate cannot be obtained promptly and quinidine is available, intravenous quinidine should be used. For either drug, a 3-day course should be given with either a 1-week course of doxycycline

or a full course of treatment with atovaquone-proguanil or mefloquine.

Supported by grants from the National Institutes of Health and Medicines for Malaria Venture and a Distinguished Clinical Scientist Award from the Doris Duke Charitable Foundation.

No potential conflicts of interest relevant to this article were reported.

I thank Dr. Nicholas J. White for a critical review of an earlier draft of this manuscript and helpful suggestions.

REFERENCES

- Greenwood BM, Bojang K, Whitty CJ, Targett GA. Malaria. *Lancet* 2005;365:1487-98.
- World Health Organization, Communicable diseases cluster: severe falciparum malaria. *Trans R Soc Trop Med Hyg* 2000;94:Suppl 1:S1-S90. (Also available at http://www.who.int/malaria/docs/hbsm_toc.htm.)
- Hoffman SL, Campbell CC, White NJ. Malaria. In: Guerrant RL, Walker DH, Weller PF, eds. *Tropical infectious diseases: principles, pathogens, & practice*. 2nd ed. Vol. 2. Philadelphia: Churchill Livingstone, 2006:1024-62.
- Desai M, ter Kuile FO, Nosten F, et al. Epidemiology and burden of malaria in pregnancy. *Lancet Infect Dis* 2007;7:93-104.
- Chen LH, Wilson ME, Schlagenhauf P. Controversies and misconceptions in malaria chemoprophylaxis for travelers. *JAMA* 2007;297:2251-63.
- Freedman DO, Weld LH, Kozarsky PE, et al. Spectrum of disease and relation to place of exposure among ill returned travelers. *N Engl J Med* 2006;354:119-30. [Erratum, *N Engl J Med* 2006;355:967.]
- Thwing J, Skarbinski J, Newman RD, et al. Malaria surveillance — United States, 2005. *MMWR Surveill Summ* 2007;56(SS-6):23-40.
- Ladhani S, Aibara RJ, Riordan FA, Shingadia D. Imported malaria in children: a review of clinical studies. *Lancet Infect Dis* 2007;7:349-57.
- Newman RD, Parise ME, Barber AM, Steketee RW. Malaria-related deaths among U.S. travelers, 1963-2000. *Ann Intern Med* 2004;141:547-55.
- Flick K, Chen Q. var Genes, PfEMP1 and the human host. *Mol Biochem Parasitol* 2004;134:3-9.
- Mackintosh CL, Beeson JG, Marsh K. Clinical features and pathogenesis of severe malaria. *Trends Parasitol* 2004;20:597-603.
- Baird JK. Effectiveness of antimalarial drugs. *N Engl J Med* 2005;352:1565-77.
- Guidelines for the treatment of malaria. Geneva: World Health Organization, 2006. (Accessed March 28, 2008, at <http://www.who.int/malaria/docs/TreatmentGuidelines2006.pdf>.)
- Woodrow CJ, Haynes RK, Krishna S. Artemisinins. *Postgrad Med J* 2005;81:71-8.
- Meshnick SR. Artemisinin: mechanisms of action, resistance and toxicity. *Int J Parasitol* 2002;32:1655-60.
- Eckstein-Ludwig U, Webb RJ, Van Goethem ID, et al. Artemisinins target the SERCA of *Plasmodium falciparum*. *Nature* 2003;424:957-61.
- Griffith KS, Lewis LS, Mali S, Parise ME. Treatment of malaria in the United States: a systematic review. *JAMA* 2007;297:2264-77.
- White NJ, Looareesuwan S, Warrell DA. Quinine and quinidine: a comparison of EKG effects during the treatment of malaria. *J Cardiovasc Pharmacol* 1983;5:173-5.
- Pukrittayakamee S, Supanaranond W, Looareesuwan S, Vanijanonta S, White NJ. Quinine in severe falciparum malaria: evidence of declining efficacy in Thailand. *Trans R Soc Trop Med Hyg* 1994;88:324-7.
- Mutabingwa TK, Anthony D, Heller A, et al. Amodiaquine alone, amodiaquine+sulfadoxine-pyrimethamine, amodiaquine+artesunate, and artemether-lumefantrine for outpatient treatment of malaria in Tanzanian children: a four-arm randomised effectiveness trial. *Lancet* 2005;365:1474-80.
- Smithuis F, Kyaw MK, Phe O, et al. Efficacy and effectiveness of dihydroartemisinin-piperazine versus artesunate-mefloquine in falciparum malaria: an open-label randomised comparison. *Lancet* 2006;367:2075-85.
- Karema C, Fanello CI, van Overmeir C, et al. Safety and efficacy of dihydroartemisinin/piperazine (Artekin) for the treatment of uncomplicated *Plasmodium falciparum* malaria in Rwandan children. *Trans R Soc Trop Med Hyg* 2006;100:1105-11.
- Dorsey G, Staedke S, Clark TD, et al. Combination therapy for uncomplicated falciparum malaria in Ugandan children: a randomized trial. *JAMA* 2007;297:2210-9.
- Ratcliff A, Siswantoro H, Kenangalem E, et al. Two fixed-dose artemisinin combinations for drug-resistant falciparum and vivax malaria in Papua, Indonesia: an open-label randomised comparison. *Lancet* 2007;369:757-65.
- Zongo I, Dorsey G, Rouamba N, et al. Randomized comparison of amodiaquine plus sulfadoxine-pyrimethamine, artemether-lumefantrine, and dihydroartemisinin-piperazine for the treatment of uncomplicated *Plasmodium falciparum* malaria in Burkina Faso. *Clin Infect Dis* 2007;45:1453-61.
- Karunajeewa HA, Manning L, Mueller I, Ilett KF, Davis TM. Rectal administration of artemisinin derivatives for the treatment of malaria. *JAMA* 2007;297:2381-90.
- van Hensbroek MB, Onyiorah E, Jaffar S, et al. A trial of artemether or quinine in children with cerebral malaria. *N Engl J Med* 1996;335:69-75.
- Hien TT, Day NPJ, Phu NH, et al. A controlled trial of artemether or quinine in Vietnamese adults with severe falciparum malaria. *N Engl J Med* 1996;335:76-83.
- Artemether-Quinine Meta-analysis Study Group. A meta-analysis using individual patient data of trials comparing artemether with quinine in the treatment of severe falciparum malaria. *Trans R Soc Trop Med Hyg* 2001;95:637-50.
- Hien TT, Davis TM, Chuong LV, et al. Comparative pharmacokinetics of intramuscular artesunate and artemether in patients with severe falciparum malaria. *Antimicrob Agents Chemother* 2004;48:4234-9. [Erratum, *Antimicrob Agents Chemother* 2005;49:871.]
- Dondorp A, Nosten F, Stepniewska K, Day N, White N. Artesunate versus quinine for treatment of severe falciparum malaria: a randomised trial. *Lancet* 2005;366:717-25.
- Jones KL, Donegan S, Lalloo DG. Artesunate versus quinine for treating severe malaria. *Cochrane Database Syst Rev* 2007;4:CD005967.
- White NJ, Looareesuwan S, Warrell DA, Chongsuphajaisiddhi T, Bunnag D, Harinasuta T. Quinidine in falciparum malaria. *Lancet* 1981;2:1069-71.
- Phillips RE, Warrell DA, White NJ, Looareesuwan S, Karbwang J. Intravenous quinidine for the treatment of severe falciparum malaria: clinical and pharmacokinetic studies. *N Engl J Med* 1985;312:1273-8.
- Rosenthal PJ, Petersen C, Geertsma FR, Kohl S. Availability of intravenous quinidine for falciparum malaria. *N Engl J Med* 1996;335:138.
- Bruneel F, Hocqueloux L, Alberti C, et al. The clinical spectrum of severe imported falciparum malaria in the intensive care unit: report of 188 cases in adults. *Am J Respir Crit Care Med* 2003;167:684-9.
- White NJ. The management of severe falciparum malaria. *Am J Respir Crit Care Med* 2003;167:673-4.
- Day N, Dondorp AM. The management of patients with severe malaria. *Am J Trop Med Hyg* 2007;77:Suppl:29-35.
- Taylor WR, White NJ. Antimalarial drug toxicity: a review. *Drug Saf* 2004;27:25-61.
- Price R, van Vugt M, Phaipun L, et al. Adverse effects in patients with acute fal-

- ciparum malaria treated with artemisinin derivatives. *Am J Trop Med Hyg* 1999;60:547-55.
41. Ribeiro IR, Olliaro P. Safety of artemisinin and its derivatives: a review of published and unpublished clinical trials. *Med Trop (Mars)* 1998;58:Suppl:50-3.
 42. Leonardi E, Gilvary G, White NJ, Nosten F. Severe allergic reactions to oral artesunate: a report of two cases. *Trans R Soc Trop Med Hyg* 2001;95:182-3.
 43. Brewer TG, Grate SJ, Peggins JO, et al. Fatal neurotoxicity of arteether and artemether. *Am J Trop Med Hyg* 1994;51:251-9.
 44. Nontprasert A, Pukrittayakamee S, Nosten-Bertrand M, Vanijanonta S, White NJ. Studies of the neurotoxicity of oral artemisinin derivatives in mice. *Am J Trop Med Hyg* 2000;62:409-12.
 45. Miller LG, Panosian CB. Ataxia and slurred speech after artesunate treatment for falciparum malaria. *N Engl J Med* 1997;336:1328.
 46. Toovey S, Jamieson A. Audiometric changes associated with the treatment of uncomplicated falciparum malaria with co-artemether. *Trans R Soc Trop Med Hyg* 2004;98:261-9.
 47. Hutagalung R, Htoo H, Nwee P, et al. A case-control auditory evaluation of patients treated with artemether-lumefantrine. *Am J Trop Med Hyg* 2006;74:211-4.
 48. Kissinger E, Hien TT, Hung NT, et al. Clinical and neurophysiological study of the effects of multiple doses of artemisinin on brain-stem function in Vietnamese patients. *Am J Trop Med Hyg* 2000;63:48-55.
 49. Van Vugt M, Angus BJ, Price RN, et al. A case-control auditory evaluation of patients treated with artemisinin derivatives for multidrug-resistant *Plasmodium falciparum* malaria. *Am J Trop Med Hyg* 2000;62:65-9.
 50. Clark RL, White TE, A Clode S, Gaunt I, Winstanley P, Ward SA. Developmental toxicity of artesunate and an artesunate combination in the rat and rabbit. *Birth Defects Res B Dev Reprod Toxicol* 2004;71:380-94.
 51. McGready R, Cho T, Keo NK, et al. Artemisinin antimalarials in pregnancy: a prospective treatment study of 539 episodes of multidrug-resistant *Plasmodium falciparum*. *Clin Infect Dis* 2001;33:2009-16.
 52. Deen JL, von Seidlein L, Pinder M, Walraven GE, Greenwood BM. The safety of the combination artesunate and pyrimethamine-sulfadoxine given during pregnancy. *Trans R Soc Trop Med Hyg* 2001;95:424-8.
 53. Jambou R, Legrand E, Niang M, et al. Resistance of *Plasmodium falciparum* field isolates to in-vitro artemether and point mutations of the SERCA-type PfATPase6. *Lancet* 2005;366:1960-3.
 54. Resistance to artemisinin derivatives along the Thai-Cambodian border. *Wkly Epidemiol Rec* 2007;82:360.
 55. Assessment of the safety of artemisinin compounds in pregnancy. Geneva: World Health Organization, 2007. (Accessed March 28, 2008, at http://malaria.who.int/docs/mip/artemisinin_compounds_pregnancy.pdf)

Copyright © 2008 Massachusetts Medical Society.

COLLECTIONS OF ARTICLES ON THE JOURNAL'S WEB SITE

The Journal's Web site (www.nejm.org) sorts published articles into more than 50 distinct clinical collections, which can be used as convenient entry points to clinical content. In each collection, articles are cited in reverse chronological order, with the most recent first.