

Microembolism during Foam Sclerotherapy of Varicose Veins

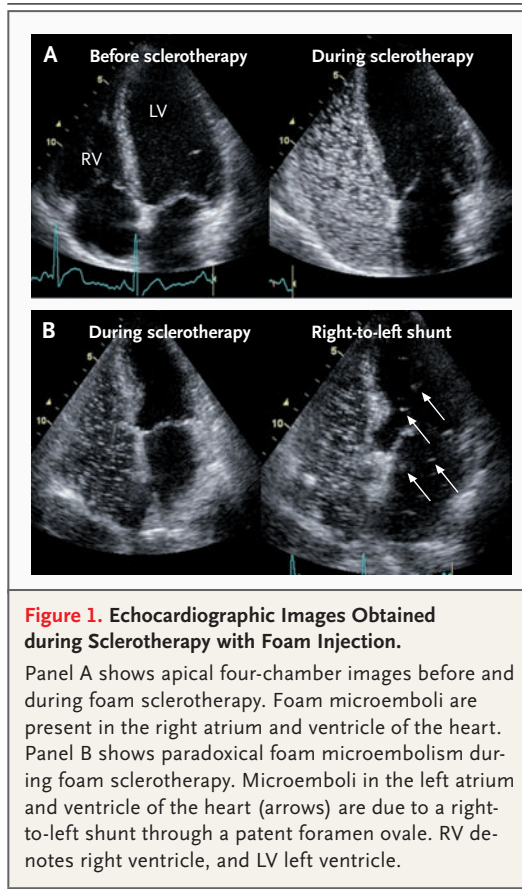
TO THE EDITOR: Chronic venous insufficiency is a common disease in adulthood. One recently developed therapy for varicose veins is foam sclerotherapy.¹

We used foam sclerotherapy in a 51-year-old man and a 33-year-old woman who had symptomatic varicose great saphenous veins and were otherwise healthy. Immediately after the initiation of treatment, transient scotomas developed in the man, and a migraine attack in the woman.

On the basis of these observations, we decided to monitor by echocardiography the foam distribution during foam sclerotherapy in 33 consecutive patients with chronic venous insufficiency. The treatment in each patient was carried out according to European consensus guidelines.² Briefly, patients received a single injection of 5 ml of 1% polidocanol foam (air-to-liquid ratio, 4:1). The foam was injected with the patient's leg slightly elevated, while the sapheno-femoral junction was manually compressed until full vasospasm occurred and blood-flow velocity in the great saphenous vein decreased to zero.

In all patients studied, we detected foam microemboli in both the right atrium and ventricle between 45 seconds and 15 minutes after foam injection (Fig. 1A). In five patients, microembolism was also detectable in the left atrium and ventricle (Fig. 1B); however, neurologic signs did not develop in any of them. Careful echocardiographic examination of these five patients showed a right-to-left shunt through a patent foramen ovale. Because the neurologic symptoms observed in the two index patients could have reflected adverse effects of foam sclerotherapy due to a right-to-left shunt, we subsequently examined both patients by echocardiography and detected a patent foramen ovale in each.

These findings suggest that foam-induced microembolism is a common phenomenon during foam sclerotherapy. The prevalence of patent foramen ovale, which can be a source of paradoxical embolism, is approximately 26% in the general population.³ Still, serious neurologic symptoms after foam sclerotherapy, which include scotomas, migraine, and stroke, occur in only 2% or less of patients.^{4,5} Thus, the findings in our cohort are in line with previous reports. Although the overall number of neurologic adverse



effects during foam sclerotherapy might be underestimated, it appears that neurologic complications develop in relatively few patients with right-to-left shunts and foam microembolism.

Nevertheless, we suggest that caution be exercised when foam sclerotherapy is performed in patients with a known patent foramen ovale and that patients with overt neurologic symptoms undergo an additional echocardiographic examination for the presence of a patent foramen ovale. Further prospective studies are needed to evaluate and confirm our observations.

Roeland P.M. Ceulen, M.D.

Anja Sommer, M.D., Ph.D.

GROW School for Oncology and Developmental Biology
6202 AZ Maastricht, the Netherlands
rpmceulen@gmail.com

Kevin Vernooij, M.D., Ph.D.

Cardiovascular Research Institute Maastricht
6200 MD Maastricht, the Netherlands

1. Jia X, Mowatt G, Burr JM, Cassar K, Cook J, Fraser C. Systematic review of foam sclerotherapy for varicose veins. *Br J Surg* 2007;94:925-36.
2. Breu FX, Guggenbichler S. European Consensus Meeting on Foam Sclerotherapy, April 4-6, 2003, Tegernsee, Germany. *Dermatol Surg* 2004;30:709-17.
3. Meier B, Lock JE. Contemporary management of patent foramen ovale. *Circulation* 2003;107:5-9.
4. Forlee MV, Grouden M, Moore DJ, Shanik G. Stroke after varicose vein foam injection sclerotherapy. *J Vasc Surg* 2006;43:162-4.
5. Guex JJ, Allaert FA, Gillet JL, Chleir F. Immediate and mid-term complications of sclerotherapy: report of a prospective multicenter registry of 12,173 sclerotherapy sessions. *Dermatol Surg* 2005;31:123-8.

Correspondence Copyright © 2008 Massachusetts Medical Society.

INSTRUCTIONS FOR LETTERS TO THE EDITOR

Letters to the Editor are considered for publication, subject to editing and abridgment, provided they do not contain material that has been submitted or published elsewhere. Please note the following:

- Letters in reference to a *Journal* article must not exceed 175 words (excluding references) and must be received within 3 weeks after publication of the article. Letters not related to a *Journal* article must not exceed 400 words. All letters must be submitted over the Internet at <http://authors.nejm.org>.
- A letter can have no more than five references and one figure or table. • A letter can be signed by no more than three authors.
- Financial associations or other possible conflicts of interest must be disclosed. (Such disclosures will be published with the letters. For authors of *Journal* articles who are responding to letters, this information appears in the published articles.)
- Include your full mailing address, telephone number, fax number, and e-mail address with your letter.

Our Web site: <http://authors.nejm.org>

We cannot acknowledge receipt of your letter, but we will notify you when we have made a decision about publication. Letters that do not adhere to these instructions will not be considered. Rejected letters and figures will not be returned. We are unable to provide prepublication proofs. Submission of a letter constitutes permission for the Massachusetts Medical Society, its licensees, and its assignees to use it in the *Journal's* various print and electronic publications and in collections, revisions, and any other form or medium.